

Developmental Dysplasia of the Hip

Scott Yang, MD,^a Natalie Zusman, MD,^a Elizabeth Lieberman, MD,^a Rachel Y. Goldstein, MD^b

Pediatricians are often the first to identify developmental dysplasia of the hip (DDH) and direct subsequent appropriate treatment. The general treatment principle of DDH is to obtain and maintain a concentric reduction of the femoral head in the acetabulum. Achieving this goal can range from less-invasive bracing treatments to more-invasive surgical treatment depending on the age and complexity of the dysplasia. In this review, we summarize the current trends and treatment principles in the diagnosis and treatment of DDH.

abstract

Developmental dysplasia of the hip (DDH) encompasses a broad spectrum of abnormal hip development during infancy and early development. The definition encompasses a wide range of severity, from mild acetabular dysplasia without hip dislocation to frank hip dislocation. The etiology of DDH is multifactorial. Risk factors for DDH are breech positioning in utero, female sex, being firstborn, and positive family history.¹⁻⁴ Other conditions related to prenatal positioning, including metatarsus adductus and torticollis, are associated with DDH. Prolonged abnormal postnatal positioning via swaddling also has been suggested as a risk factor in DDH because certain ethnic populations that practice tight swaddling have a higher rate of DDH.^{5,6} The treatment algorithm in patients with DDH depends on each patient's age and severity of the condition. The goal in the treatment of DDH is to achieve and maintain a concentric reduction of the femoral head in the acetabulum to allow for continued normal development of the hip. The natural history of residual DDH or dislocation into adulthood has been associated with pain and early development of osteoarthritis. Residual sequelae of DDH are 1 of the leading causes of early hip osteoarthritis in adulthood.⁷ Hence, the goal is to improve hip development in

infancy and early childhood to prevent subsequent functional impairment.

A variety of methods are available achieve the overarching goal of obtaining a concentric hip reduction. The treatment methods and goals have not drastically changed in the past 20 years, although recent developments within the past 5 to 10 years have been focused on optimal surveillance methods, imaging modalities to guide treatment, outcomes assessment of treatment methods, and refining indications for treatment. It is important for both the clinicians and families to understand that the treatment of a dysplastic hip can be challenging and met with complications.

Although variations in treatment exist based on individual patient characteristics, the following algorithm is generally considered (Table 1). Infants up to 6 months of age who are confirmed to have hip instability or dislocation are generally treated with a brace initially, such as a Pavlik harness or abduction orthosis. Patients aged 6 to 18 months with dislocation can be treated with closed reduction and the application of a hip spica cast. Generally, patients >12 to 18 months of age or those who fail to achieve a concentric hip reduction with closed methods are considered candidates for open surgical hip reduction. There are outliers to this general algorithm

^aDepartment of Orthopedics and Rehabilitation, Doernbecher Children's Hospital and Oregon Health and Science University, Portland, Oregon; and ^bChildren's Orthopaedic Center, Children's Hospital Los Angeles, Los Angeles, California

Dr Yang conceptualized and drafted the initial manuscript and edited the final manuscript; Drs Zusman and Lieberman drafted the initial manuscript; Dr Goldstein provided content guidance and edited and provided critical revisions to the manuscript; and all authors approved the final manuscript as submitted.

DOI: <https://doi.org/10.1542/peds.2018-1147>

Accepted for publication Sep 7, 2018

Address correspondence to Scott Yang, MD, Department of Orthopedics and Rehabilitation, Doernbecher Children's Hospital, 3181 SW Sam Jackson Park Rd, Mail Code CDW6, Portland, OR 97239. E-mail: yansc@ohsu.edu

PEDIATRICS (ISSN Numbers: Print, 0031-4005; Online, 1098-4275).

Copyright © 2019 by the American Academy of Pediatrics

FINANCIAL DISCLOSURE: The authors have indicated they have no financial relationships relevant to this article to disclose.

FUNDING: No external funding.

POTENTIAL CONFLICT OF INTEREST: The authors have indicated they have no potential conflicts of interest to disclose.

To cite: Yang S, Zusman N, Lieberman E, et al. Developmental Dysplasia of the Hip. *Pediatrics*. 2019;143(1):e20181147

TABLE 1 General Treatment Algorithm for Hip Dislocation

Age	Treatment	Comments
<6 mo	Abduction orthosis (ie, Pavlik harness)	—
6–18 mo	Closed reduction under general anesthesia with hip spica cast	Closed reduction at <6 mo of age if abduction orthosis attempt fails
>12–18 mo	Open hip reduction	Open reduction <1 y of age if previous closed-reduction attempt fails
>2 y	Open hip reduction with or without femoral shortening osteotomy	Femoral shortening osteotomy may, but not always, be needed on the basis of the amount of tension that needs to be relieved to achieve a hip reduction.
3–8 y	Open hip reduction with or without femoral shortening osteotomy and with or without pelvic osteotomy	Pelvic osteotomy may, but not always, be needed to address residual acetabular dysplasia.
>8 y	Open hip reduction versus observation for eventual arthroplasty	Controversial; poorer outcomes noted in attempting hip open reductions in those >8 y old

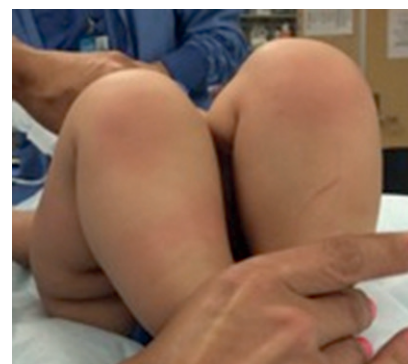because children <6 months old may occasionally require closed or open hip reduction if bracing treatment fails. Osteotomies, such as femoral shortening osteotomy and pelvic osteotomy, are considered for hip dislocation in older patients to decrease tension on the hip reduction and those with a residual shallow dysplastic acetabulum, respectively. Adolescents and young adults with residual symptomatic acetabular dysplasia are treated with periacetabular osteotomy (PAO) to preserve the native hip joint and avoid hip arthroplasty. Recent developments in each of these treatment methods will be discussed in this article.

HIP EXAMINATION

Early identification of infants with dysplastic hips can be performed on a routine basis from the newborn physical examination and continue until the child reaches walking age.⁸ A newborn infant's hips should be evaluated by using the Barlow and Ortolani physical examination maneuvers. The Barlow maneuver is performed by adducting the hip to the midline and gently applying posterior force. A positive Barlow result is when the femoral head subluxes, and a clunk is felt. A Barlow-positive hip indicates that the femoral head is resting in the acetabulum but has pathologic instability. With the thighs adducted and posteriorly depressed, the Ortolani maneuver is performed by

abducting the hips while applying anterior-directed pressure at the greater trochanters. An Ortolani maneuver is considered to have a positive result if the femoral head relocates with a distinct clunk. An Ortolani-positive hip is more severe than a Barlow-positive hip because it indicates that the femoral head is dislocated at rest. The presence of a subtler hip click during examination is a nonspecific finding and often does not indicate true hip pathology.^{9,10} The 2 major limitations of these maneuvers are their dependence on the skill of the examining provider and the fact that these tests are more sensitive in younger infants, whose soft tissues around the hip joint have yet to contract. Furthermore, a severely dislocated hip that is not reducible may not have a Barlow or Ortolani positive result. The sensitivity of Barlow and Ortolani examination maneuvers alone in identifying DDH is at best 54%¹¹; thus, adjunct imaging modalities for identification can be helpful.

For the older infant or child, Barlow and Ortolani examination is of limited utility due to the development of contractures. These patients are observed for leg length discrepancy, thigh-fold asymmetry, and limited hip abduction. Leg length discrepancy should be assessed for with the infant in the supine position with the pelvis flat on a level surface and the hips and knees flexed to 90°. A discrepancy is indicated by unequal knee heights, which is termed the Galeazzi sign (Fig 1). Asymmetric

**FIGURE 1**

Galeazzi sign. With the pelvis level on a flat surface, the heights of the knees are asymmetric. The right knee height is shorter, suggesting possible hip dislocation.

thigh folds and clinical examination of limb length discrepancy are prone to error and inaccuracy. The most sensitive examination for unilateral hip dislocation in a child >3 months old is an assessment for asymmetric diminished hip abduction (Fig 2).^{12,13} The walking child may also present with a Trendelenburg gait (trunk tilt toward the affected hip when weight is applied) if there is a unilateral dislocation or a waddling gait (trunk tilt toward the weight-bearing side, alternating throughout the gait cycle) if there is bilateral dislocation. For infants who are Ortolani-positive or older children with any of the above examination findings, further diagnostic evaluation can be obtained, as described below.

DIAGNOSTICS: IMAGING STUDIES

Ultrasonography is the recommended imaging modality in infants <4

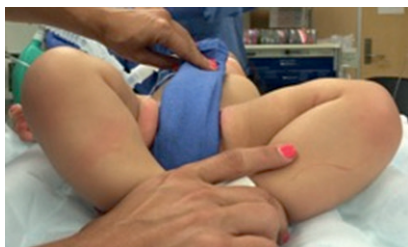

FIGURE 2
The right hip has limited abduction compared with the left, suggesting possible hip dislocation.

months old because the infant hip is predominantly cartilaginous, precluding clear radiographic visualization. Ultrasonography allows for the visualization of the femoral head location relative to the acetabulum and specific anatomic parameters, such as the depth of the acetabulum and inclination of the acetabular roof. Key ultrasound measures are depicted in Fig 3. The imaging modality can be performed in a static or dynamic manner. In a static study, researchers examine the joint anatomy (ie, the shapes and relations between the femoral head, acetabulum, and labrum). During a dynamic ultrasonography, hip joint stability is assessed by performing the manipulative stress maneuvers under direct imaging observation. Ultrasonography can be used for both initial infant screening of DDH and monitoring of patients with DDH undergoing active treatment. The femoral head ossification nucleus is visible radiographically at ~4 to 6 months of age. Hence, radiographs are not recommended for DDH evaluations before 4 months of age. After ~6 months of age, radiographs are the preferred method of evaluating and monitoring DDH after femoral head ossification more reliably appears. It is important to note that the affected hip in DDH often demonstrates a delayed radiographic appearance of the femoral head ossification center. Key radiographic measures and angles are depicted in Fig 4.

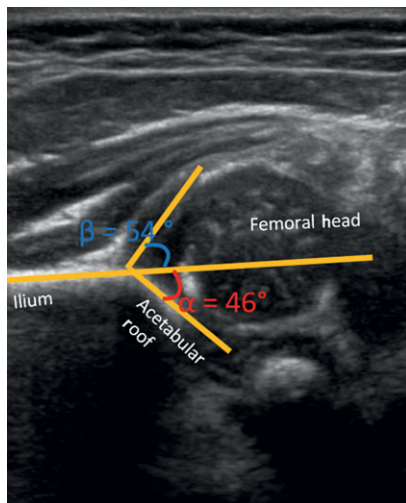


FIGURE 3
Coronal ultrasound images of a 2-month-old dysplastic hip. Key ultrasound measurements include the α (which is formed by the bony ilium and the bony roof of the acetabulum), the β angle (which is formed by the bony ilium and the labral fibrocartilage), and the percentage of the femoral head covered by the bony roof of the acetabulum. The α angle has more clinical significance than the β angle. In this image, (1) the femoral head does not seat deeply in the socket, with <50% of the femoral head being covered by the acetabulum, and (2) the acetabulum is shallow (normal $\alpha > 60^\circ$).

EARLY IDENTIFICATION AND SURVEILLANCE

The optimal method to screen for DDH is controversial. The goal of screening in DDH is to both prevent undiagnosed cases and allow for earlier, less-aggressive interventions to achieve hip reduction. One difficulty with screening DDH is that there is no uniform pathology that characterizes DDH because the definition encompasses mild acetabular dysplasia to frank dislocation. Although the early natural history is more clearly understood in cases of untreated hip dislocation, the long-term history of mild acetabular dysplasia identified with ultrasound in infancy is unclear. The normal immature hip can demonstrate instability, such as a Barlow-positive examination result or dynamic ultrasonography evidence instability, due to ligamentous laxity during the early neonatal period. With normal

maturation, these early pathologic findings often resolve spontaneously with time.

Previously, the US Preventive Services Task Force published a report in 2006 in which it concluded that there was insufficient evidence to support routine screening for DDH in infants to prevent future adverse outcomes.¹⁴ However, this recommendation was met with controversy because DDH is difficult to identify without a focused examination, can lead to significant disability if left untreated, and is more easily treated at a young age during infancy. Subsequently, the American Academy of Pediatrics (AAP) recommends continuing periodic newborn physical examination surveillance throughout infancy.

Controversy exists as to what is the best screening method. Several methods include physical examination alone, physical examination with a selective use of ultrasonography, and universal screening with ultrasonography. There has been no comparative study of outcomes in patients who have not been screened versus those who underwent a screening program for DDH. Ultrasonography has been demonstrated to be used to identify potentially pathologic hips more than clinical examination alone. Dezateux and Rosendahl¹⁵ reported that the identification of dysplastic hips in general populations increased from 1.6 to 28.5 per 1000 infants, with clinical examination increasing from 34.0 to 60.3 per 1000 infants with the use of screening ultrasonography. Studies in which researchers compare clinical examination and selective ultrasonography to universal ultrasonography revealed no significant difference in decreasing the late presentation of DDH.^{16,17} A 2013 Cochrane Review on the topic echoed this conclusion with the findings that targeted screening is not associated with significant

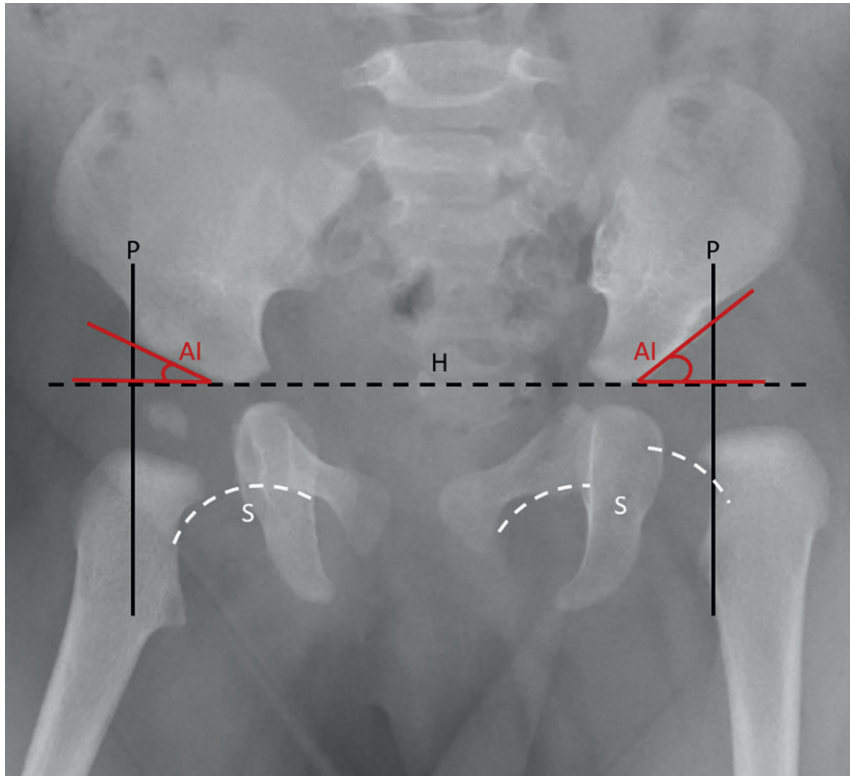


FIGURE 4

AP pelvis radiograph of a left-hip dislocation. On an AP pelvis radiograph, classic measurements include drawing several lines to help identify dysplasia. H is drawn as a horizontal line, connecting the bilateral acetabular triradiate cartilage. P is then drawn perpendicular to H at the lateral edge of the acetabulum. In the normal right hip, the ossific nucleus rests along the bottom-inner quadrant formed by the intersection of the 2 lines. In the dislocated hip, the ossific nucleus rests lateral to the intersection of the 2 lines. S should reveal a smooth arch from the obturator foramen to the inferior aspect of the femoral neck, as in the right hip. S is disrupted on the left hip, suggesting dislocation. The acetabular index is the angle formed along the acetabular roof and H, with steeper values indicating acetabular dysplasia. Notice also that the left femoral head ossific nucleus is smaller; and its appearance is more delayed compared with the nondysplastic side. AI, acetabular index; AP, anteroposterior; H, Hilgenreiner line; P, Perkins line; S, arc of Shenton.

increases in late diagnoses when compared with universal screening and is associated with a reduction in potential overtreatment.¹⁸ The American Academy of Orthopaedic Surgeons also provided a moderate-strength recommendation supporting not performing universal screening ultrasound in newborns in its recent clinical practice guideline.¹⁹ Because many milder forms of DDH have a benign natural history, this increased identification of DDH can potentially lead to overtreatment. The true natural history of mild acetabular dysplasia on a well-located hip on ultrasonography is unclear because many can improve without intervention, as evidenced

on serial ultrasonography.²⁰ Olsen et al²¹ identified that adding universal ultrasound to clinical screening doubled the early-brace treatment rate without a significant decrease in late-presenting DDH.

The AAP has recently published a best practice clinical report based on best available evidence.⁸ These guidelines include a healthy balance of adequate identification and prevention of overtreatment in mild forms of DDH. Key recommendations include that routine newborn and periodic physical examinations should be performed by pediatricians to clinically detect DDH. Evidence is used to support treating hip dislocation (Ortolani-positive test

result) while initially observing milder instability (Barlow-positive test result). Targeted ultrasonography evaluation of infants 6 weeks to 6 months old can be obtained on the basis of consultation with a pediatric radiologist or orthopedist, although universal ultrasonography screening is not routinely recommended. On whom to obtain an ultrasound can be further elucidated in the American Academy of Orthopaedic Surgeons clinical practice guidelines. This report included a moderate recommendation for performing a screening imaging study for infants <6 months old with 1 or more of the significant risk factors: breech position, history of clinical instability, and positive family history.¹⁹ Finally, in the AAP guidelines, the authors state that parents should avoid tight swaddling of the lower extremities that places the hips into adduction to minimize the risk of DDH. Tight swaddling can lead to excess prolonged stress on the hips, leading to instability. Thus, the AAP and Pediatric Orthopaedic Society of North America recommend that infant hips should have freedom of flexion and abduction during swaddling.²²

EARLY BRACE MANAGEMENT

For infants up to 6 months of age, the Pavlik harness (Fig 5) has classically been used for the stabilization of the dysplastic hip. The Pavlik harness is used to hold the hips in a position of flexion and abduction that allows for the centering of the femoral head in the acetabulum. Recent studies on the use of the Pavlik harness help us understand which patients have successful outcomes and those who are at risk for failure of harness treatment. The Barlow-positive hip has been demonstrated to have >90% successful stabilization with a Pavlik harness. The Ortolani-positive, or initially dislocated, hip

is more problematic and has had Pavlik harness failure in 21% to 37% of patients.²³⁻²⁵ Patient-related risk factors for failure of harness treatment included increased age at initiation of treatment (>7 weeks old),^{25,26} multigravida birth,²⁷ the presence of a foot deformity,²⁷ and male sex.²⁴ The initial ultrasonographic severity of dysplasia in the Ortolani-positive hip is prognostic for the failure of Pavlik harness treatment, with more severely dislocated hips in which the labrum is interposed between the femoral head and acetabulum being associated with failure.²³

For those patients with an Ortolani-positive hip who fail to stabilize after initial Pavlik harness treatment, authors of recent literature suggest that a trial of a more rigid abduction hip orthosis, such as an Ilfeld orthosis (Fig 6), may obviate the need for either closed or open reduction in the operating room. Sankar et al²⁸ demonstrated that a stable hip reduction was achieved in 82% of patients who underwent rigid orthosis treatment after Pavlik harness failure in Ortolani-positive hips, with equivalent radiographic outcomes to closed reduction and casting being observed. Rigid abduction orthotic management allows for an alternative pathway to avoiding general anesthesia and casting in young children.

Complications of the Pavlik harness or abduction orthoses are rare, although they can include avascular necrosis (AVN) of the femoral head, skin irritation, and femoral nerve palsy. Femoral nerve palsy is apparent when the infant stops demonstrating spontaneous knee extension while in the Pavlik harness. In a recent study, researchers compiled cases of femoral nerve palsy with Pavlik harness treatment and demonstrated that all patients recovered nerve function after the discontinuation or loosening of the Pavlik harness straps.²⁹ More

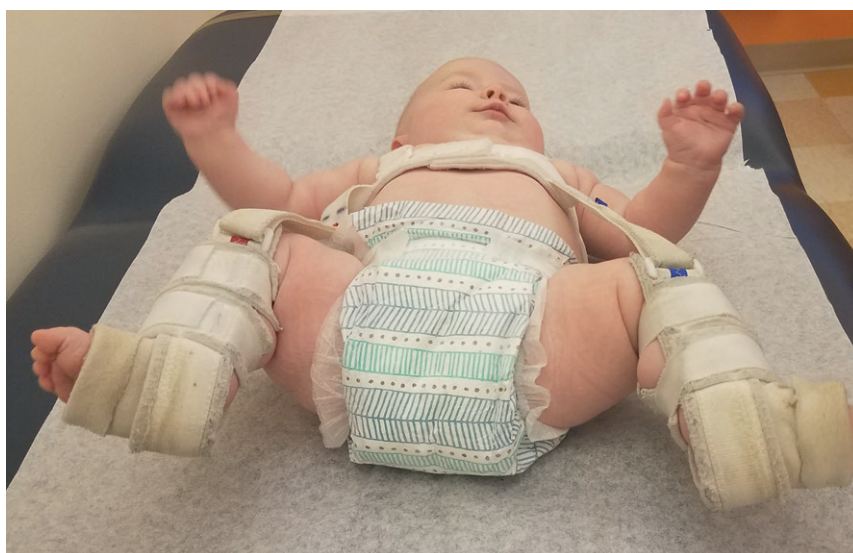

FIGURE 5

Pavlik harness on an infant, gently holding the hips in a flexed and abducted position.

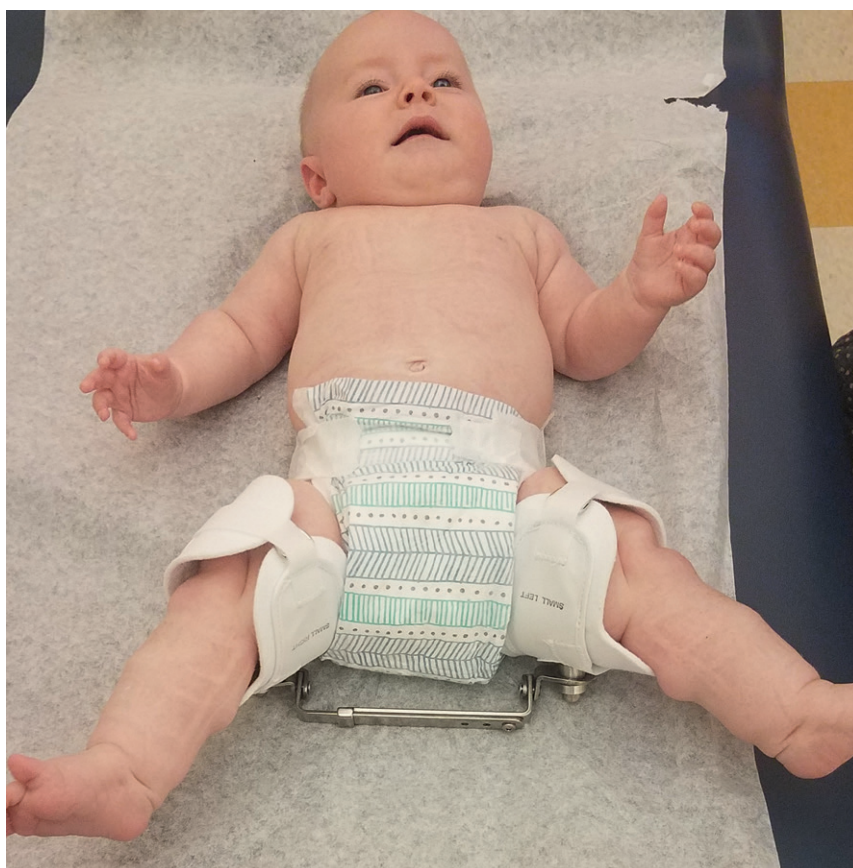

FIGURE 6

Ilfeld abduction orthosis on a patient. This orthosis allows for the hips to be held more rigidly in abduction than a Pavlik harness.

importantly, patients who developed femoral nerve palsy had a high (47%) failure rate of Pavlik harness

treatment, possibly indicating that this complication occurs in more severe cases of DDH or that the

cessation of harness due to nerve palsy contributed to the failures.

For patients who underwent successful treatment with the Pavlik harness, researchers in several studies elucidate which patients need further radiographic monitoring for residual acetabular dysplasia. Patients with initial severe ultrasonographic hip dislocations are associated with abnormal radiographic acetabular development at 1 year of age and may need further radiographic monitoring throughout their growth.³⁰ However, patients with normal radiographic acetabular development by age 2 years after successful Pavlik harness treatment have all demonstrated continued normal acetabular development at a mean of 10 years' follow-up, suggesting that further radiographic surveillance after a normal radiograph result at age 2 years is not necessary.³¹

HIP REDUCTION

In older infants with untreated hip dislocations (generally 6–18 months) or those who failed early brace treatment of hip stabilization, closed reduction and hip spica casting is next in the treatment algorithm. The technique or indication for closed reduction has not significantly changed over time, yet our understanding of the outcomes of the procedure continues to expand. Closed reduction is performed under general anesthesia, the hip is placed in 90° to 100° of flexion, and the minimal amount of abduction necessary to maintain a stable hip reduction is sustained. Failure of reduction or redislocation can occur in up to 13.6% of cases.³²

AVN of the femoral head and the associated proximal femoral growth disturbance is the most feared and frequent complication of this procedure. Several etiologies and risk factors for this complication

have been recently studied, including age, radiographic presence of the ossific nucleus, and abduction angle in the cast. A prospective study revealed that AVN occurs in up to 25% of patients after closed reduction and casting of the hip.³³ A major current focus among pediatric orthopedic surgeons is on minimizing this complication. Previously, the presence of a radiographic ossific nucleus (which usually appears at ~4–6 months old in normal hips) and older age were regarded as protective from developing AVN, with the theory being that the cartilaginous femoral head is more susceptible to ischemic damage from pressure.^{34,35} These claims remain controversial, with more recent literature revealing no such association, and thus no clear benefit in waiting until ossification of the femoral head occurs to reduce the hip.^{36–38} Traction applied to the lower extremity to facilitate a gradual stretching of the contracted tissues of the hip has previously been thought to reduce the risk of AVN via a more gentle, graduated correction than a closed reduction without traction. Sucato et al³⁹ recently reported their findings on the largest series of traction used before hip reduction for dislocated hips in those <3 years of age and demonstrated no major difference in successful closed reduction and AVN rates in patients who were treated with traction compared with those who were not. Hence, traction is not routinely recommended because of caregiver and potential patient burden without a clear benefit in outcome. It is thought that excessive abduction of the hip leads to increased pressure on the femoral head and subsequently to impaired perfusion of the femoral head. Schur et al⁴⁰ demonstrated an up to 60% AVN rate in patients <6 months of age if the hip abduction in the hip spica cast was >50°. Newer contrast perfusion MRI protocols have been used in some centers to evaluate perfusion of the

femoral head after casting. In 1 study, no patients with a normal perfusion MRI result after casting developed AVN.⁴¹ This modality is promising and theoretically allows for checking the perfusion of the femoral heads and the correction of excessive hip abduction in the cast before the development of permanent femoral head ischemia.

Generally, in patients >12 to 18 months of age or younger patients who failed closed reduction, an open surgical approach is recommended to remove anatomic blocks to achieving a concentric hip reduction. Recent advancements in open reduction are similarly focused on understanding risk factors for developing surgical complications. Open reduction can be performed via an anterior- or medial-based surgical approach to the hip. The medial approach is less invasive and does not require splitting the iliac apophysis. The anterior approach is more classic and allows for more comprehensive access to the acetabulum and the barriers to reduction. Furthermore, a capsulorrhaphy (surgically tightening the hip capsule to maintain hip stability) is only possible with an anterior approach. Proponents of either surgical approach may cite a decreased risk of AVN as the main indication of choosing 1 over the other, although no researchers have conclusively demonstrated that 1 approach is more prone to the development of AVN. The surgical approach of choice seems to depend mostly on surgeon comfort level. AVN rates for either approach in the literature vary widely depending on the study, although pooled meta-analysis data reveal a ~20% AVN rate for open-reduction surgery (Fig 7).⁴² For older patients (generally >2 years), a femoral shortening osteotomy can be added to the open-reduction surgery to reduce tension on the long-standing contracted dislocated hip and has been shown to be beneficial in reducing AVN

and redislocation rates.⁴³ The upper age limit when performing an open reduction of a dislocated hip is unclear. Recent literature reveals that younger children (<8 years) may benefit the most from the relocation of long-standing hip dislocation. Late-diagnosed hip dislocations after age 8 years tend to do more poorly with open reduction of the hip, and whether to perform a reduction in these patients is highly debatable.^{44,45}

Pelvic Osteotomies

Acetabular dysplasia is usually characterized by a shallow and/or vertically oriented acetabulum. This leads to either inadequate coverage to contain the femoral head in a reduced position or acceleration of arthritis due to abnormal edge contact loading. In patients who have failed initial treatment and have persistent acetabular dysplasia, pelvic osteotomies may be indicated to resume a more normal development of the acetabulum. These surgeries are usually reserved for older children because the acetabulum has been shown to remodel throughout childhood up to age 5 years,⁴⁶ allowing for continued development in the presence of a well-located hip. Hence, the timing of performing the osteotomy is controversial although typically performed at ~3 to 5 years of age for residual acetabular dysplasia. The most commonly used pelvic osteotomies are termed the Salter, Pemberton, and Dega. All these osteotomies use a single cut above the acetabulum, with their differences being in the completion or direction of the cut (Fig 8). On the basis of recently available literature, the radiographic and clinical outcomes for which researchers compare the various types of osteotomy appear to be similar in the treatment of residual acetabular dysplasia.^{47–50} Although there is no clear upper-age limit guideline to the above osteotomies, it is more difficult

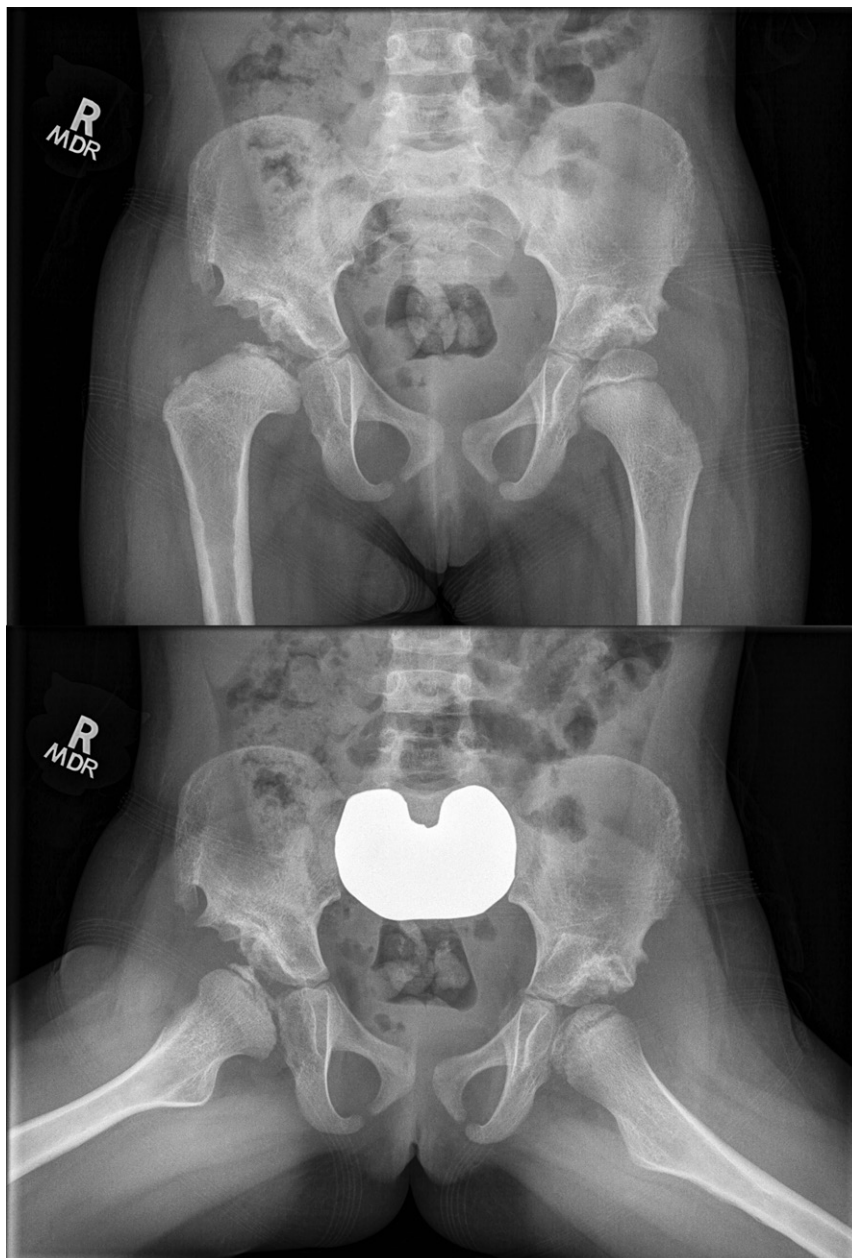


FIGURE 7

A 5-year-old girl, 2 years after right-hip open reduction, who underwent femoral and pelvic osteotomy, with the development of femoral head fragmentation and irregularity suggestive of AVN.

to achieve adequate acetabular coverage of the dysplastic hip with a single osteotomy with increasing age. For older children with an open triradiate cartilage growth center, typically >6 years of age, a triple innominate osteotomy can be considered. In the triple innominate osteotomy, all 3 osseous regions surrounding the acetabulum are cut to allow for a free reorientation of

the acetabulum and the achievement of increased correction of acetabular dysplasia (Figs 9 and 10).

At this juncture, it appears that pelvic osteotomies are useful in improving radiographic coverage of the femoral head and preventing reoperation for residual instability after open reduction. The technique of osteotomy appears to be at the discretion of the surgeon because 1

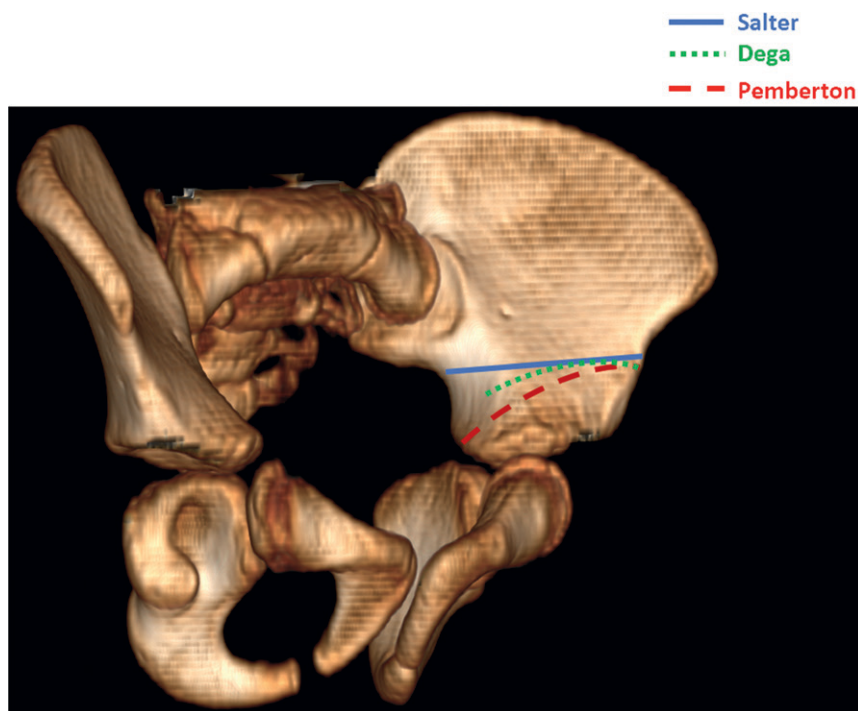


FIGURE 8
Schematic of the differences between Salter, Dega, and Pemberton osteotomies.

technique has not been definitively proven to be superior to another.

PAOs for Adolescents

There has been recent momentum in the field of adolescent and young adult hip preservation surgery, with the goal being preventing degenerative osteoarthritis related to DDH. The Bernese PAO is a technique developed in Switzerland and has gained popularity over the past several decades. In this osteotomy, specific cuts are made around the acetabulum to allow for a complete reorientation of the acetabular cartilage while maintaining an intact posterior column and without causing any structural changes to the intrapelvic space (Fig 11). The goal in an osteotomy is to realign the native acetabulum to allow for improved acetabular coverage of the femoral head (Figs 12 and 13). This theoretically improves abnormal contact forces of the hip that predispose the hip to early degenerative osteoarthritis and early hip arthroplasty.

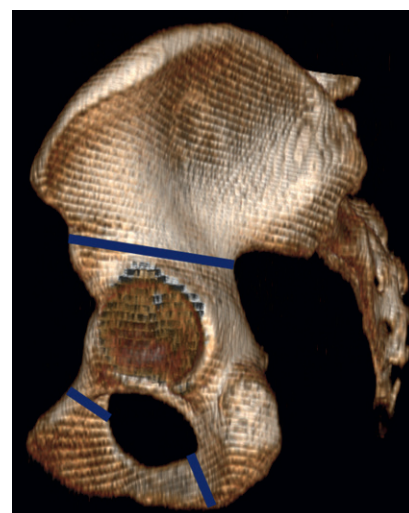


FIGURE 9
Lateral view of the pelvis, with the 3 characteristic osteotomies surrounding the acetabulum in a triple innominate osteotomy.

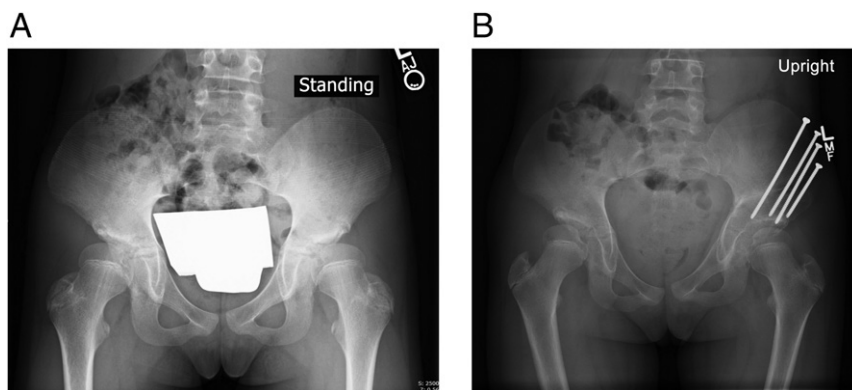


FIGURE 10
A, A 10-year-old skeletally immature girl with bilateral hip dysplasia with deficient coverage of bilateral femoral heads. B, Four months' status after left triple innominate osteotomy with improved coverage of the left femoral head.

The current indications for patients to undergo PAO include young patients with hip pain who have a closed triradiate acetabular cartilage growth center, radiographic evidence of femoral head uncoverage due to a shallow acetabulum, and a congruent hip joint without radiographic signs of arthritic degeneration. The recent developments in adolescent and young adult hip preservation surgery

are in refining patient selection as to who can most benefit from the procedure. Although a strict age cutoff for the procedure is not well defined, poorer outcomes after PAO have been associated in patients aged >35 years.⁵¹ To optimize patient selection, several centers have been using a delayed gadolinium-enhanced MRI of cartilage protocol preoperatively to specifically

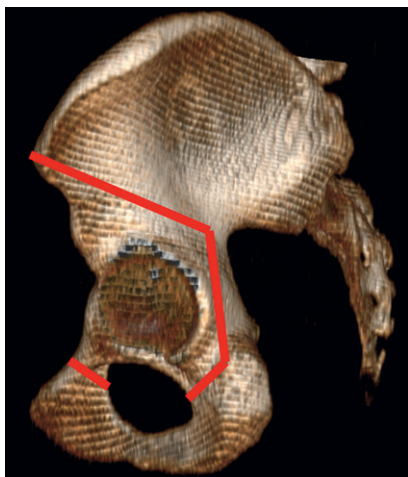


FIGURE 11

Lateral view of the pelvis, with the characteristic osteotomies surrounding the acetabulum in PAO. The posterior column of the acetabulum is preserved, which differs from a triple innominate osteotomy.

evaluate early cartilage degeneration that is not detected by using routine radiography.^{52,53} This tool can be helpful in selecting patients without cartilage degeneration who can benefit most from PAO.

Early-term and midterm outcomes of PAOs have been favorable in appropriately selected adolescents or young-adult patients. Most patients demonstrate improved hip pain symptoms after PAO. A detailed evaluation of patient-reported outcomes in the short-term revealed significant improvement in quality of life, pain, and function after PAO.⁵⁴ More modest improvements in patient-related outcomes after surgery are associated with patients with milder radiographic DDH and obesity.⁵⁴ The PAO appears to have an excellent result in the intermediate term. Several studies revealed that 93% to 95% of young patients undergoing PAO (mean age: 25.4–26 years) did not require a hip replacement at 10 years' follow-up.^{55,56} There is a paucity of long-term follow-up of PAO. The only long-term study of >30 years' follow-up revealed that as many as 71% of patients continued to

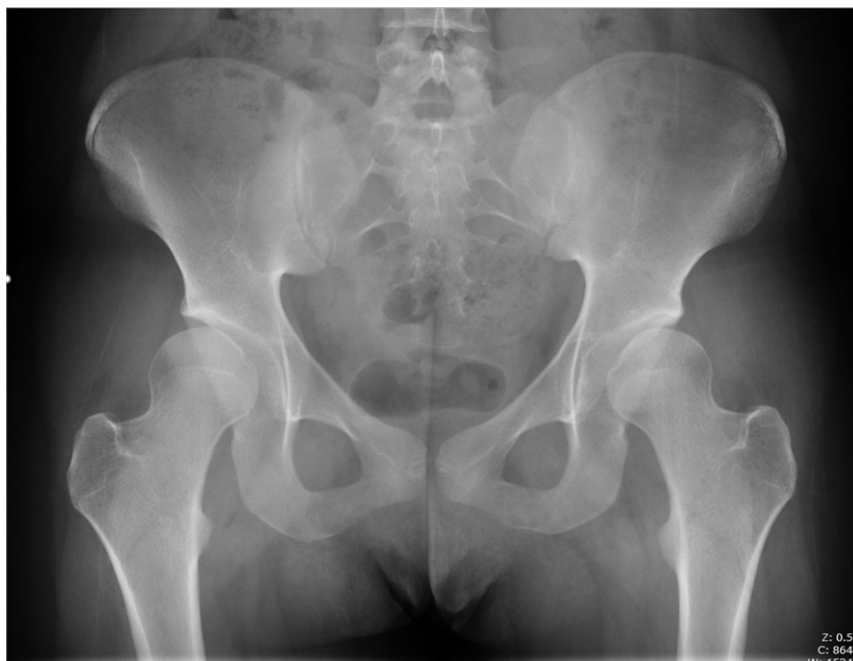

FIGURE 12

A 17-year-old skeletally mature girl with bilateral hip pain and dysplasia with deficient coverage of bilateral femoral heads.

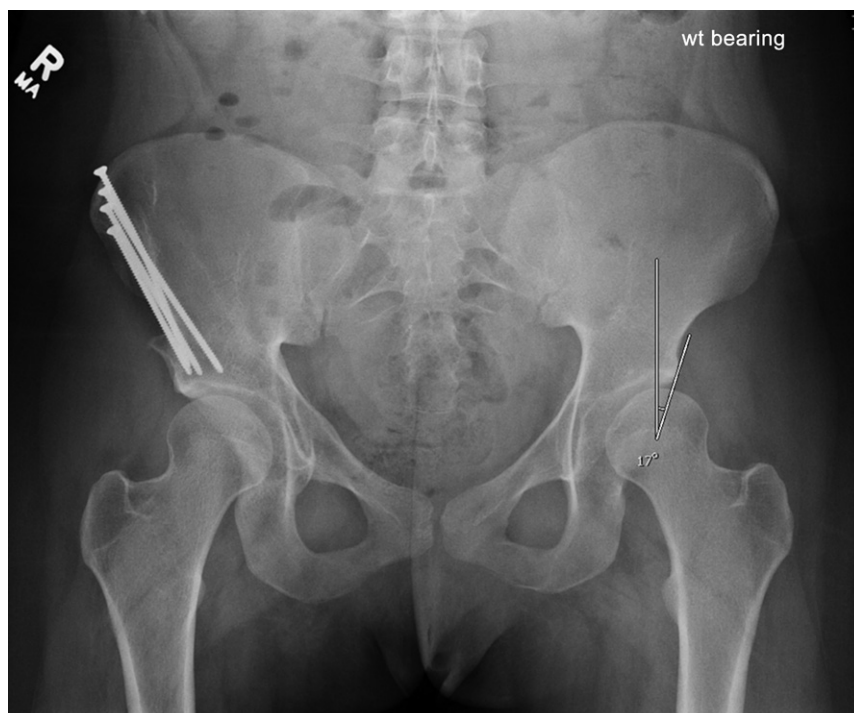

FIGURE 13

(Continued) Six months' status after right PAO with improved coverage of the right femoral head.

progress to develop pain symptoms, have radiographic evidence of osteoarthritis, or require hip replacement after PAO.⁵⁷ However,

this sample did not represent a strict selection criterion for surgery that is often used today because advanced osteoarthritis was present in 24%

of the hips before PAO in the study. More time will be required to truly appreciate the long-term benefit of the PAO procedure.

CONCLUSIONS

The treatment of DDH remains challenging, yet recent advances have refined our understanding of how best to survey for the condition during infancy, minimize complications during early treatment, and refine the selection of patients who can best benefit from hip preservation surgery. The ideal continued target would be to prevent missed hip dislocations or dysplasia during the infant period, prevent AVN during early treatment, and decrease the incidence of total hip arthroplasty in adulthood related to undertreated DDH.

ABBREVIATIONS

AAP: American Academy of Pediatrics

AVN: avascular necrosis

DDH: developmental dysplasia of the hip

PAO: periacetabular osteotomy

REFERENCES

- Ortiz-Neira CL, Paolucci EO, Donnon T. A meta-analysis of common risk factors associated with the diagnosis of developmental dysplasia of the hip in newborns. *Eur J Radiol*. 2012;81(3):e344–e351
- Panagiotopoulou N, Bitar K, Hart WJ. The association between mode of delivery and developmental dysplasia of the hip in breech infants: a systematic review of 9 cohort studies. *Acta Orthop Belg*. 2012;78(6):697–702
- Li L, Wang X, Zhao Q, et al. CX3CR1 polymorphisms associated with an increased risk of developmental dysplasia of the hip in human. *J Orthop Res*. 2017;35(2):377–380
- Stevenson DA, Mineau G, Kerber RA, Viskochil DH, Schaefer C, Roach JW. Familial predisposition to developmental dysplasia of the hip. *J Pediatr Orthop*. 2009;29(5):463–466
- Rabin DL, Barnett CR, Arnold WD, Freiburger RH, Brooks G. Untreated congenital hip disease. A study of the epidemiology, natural history, and social aspects of the disease in a Navajo population. *Am J Public Health Nations Health*. 1965;55(suppl):1–44
- Yamamuro T, Ishida K. Recent advances in the prevention, early diagnosis, and treatment of congenital dislocation of the hip in Japan. *Clin Orthop Relat Res*. 1984;(184):34–40
- Harris WH. Etiology of osteoarthritis of the hip. *Clin Orthop Relat Res*. 1986;(213):20–33
- Shaw BA, Segal LS; Section on Orthopaedics. Evaluation and referral for developmental dysplasia of the hip in infants. *Pediatrics*. 2016;138(6):e20163107
- Jones DA. Importance of the clicking hip in screening for congenital dislocation of the hip. *Lancet*. 1989;1(8638):599–601
- Bond CD, Hennrikus WL, DellaMaggiore ED. Prospective evaluation of newborn soft-tissue hip “clicks” with ultrasound. *J Pediatr Orthop*. 1997;17(2):199–201
- Rosenberg N, Bialik V, Norman D, Blazer S. The importance of combined clinical and sonographic examination of instability of the neonatal hip. *Int Orthop*. 1998;22(3):185–188
- Choudry Q, Goyal R, Paton RW. Is limitation of hip abduction a useful clinical sign in the diagnosis of developmental dysplasia of the hip? *Arch Dis Child*. 2013;98(11):862–866
- Roposch A, Liu LQ, Hefti F, Clarke NM, Wedge JH. Standardized diagnostic criteria for developmental dysplasia of the hip in early infancy. *Clin Orthop Relat Res*. 2011;469(12):3451–3461
- US Preventive Services Task Force. Screening for developmental dysplasia of the hip: recommendation statement. *Pediatrics*. 2006;117(3):898–902
- Dezateux C, Rosendahl K. Developmental dysplasia of the hip. *Lancet*. 2007;369(9572):1541–1552
- Holen KJ, Tegnander A, Bredland T, et al. Universal or selective screening of the neonatal hip using ultrasound? A prospective, randomised trial of 15,529 newborn infants. *J Bone Joint Surg Br*. 2002;84(6):886–890
- Rosendahl K, Markestad T, Lie RT. Ultrasound screening for developmental dysplasia of the hip in the neonate: the effect on treatment rate and prevalence of late cases. *Pediatrics*. 1994;94(1):47–52
- Shorter D, Hong T, Osborn DA. Cochrane review: screening programmes for developmental dysplasia of the hip in newborn infants. *Evid Based Child Health*. 2013;8(1):11–54
- Mulpuri K, Song KM, Goldberg MJ, Sevarino K. Detection and nonoperative management of pediatric developmental dysplasia of the hip in infants up to six months of age. *J Am Acad Orthop Surg*. 2015;23(3):202–205
- Rosendahl K, Dezateux C, Fosse KR, et al. Immediate treatment versus sonographic surveillance for mild hip dysplasia in newborns. *Pediatrics*. 2010;125(1). Available at: www.pediatrics.org/cgi/content/full/125/1/e9
- Olsen SF, Blom HC, Rosendahl K. Introducing universal ultrasound screening for developmental dysplasia of the hip doubled the treatment rate. *Acta Paediatr*. 2018;107(2):255–261
- American Academy of Pediatrics; Pediatric Orthopaedic Society of North America. Swaddling and developmental hip dysplasia position statement. 2015. Available at: <https://posna.org/POSNA/media/Documents/PositionStatements/SwaddlingPositionStatementApril2015.pdf>. Accessed August 1, 2018
- White KK, Sucato DJ, Agrawal S, Browne R. Ultrasonographic findings in hips with a positive Ortolani sign and their relationship to Pavlik harness failure. *J Bone Joint Surg Am*. 2010;92(1):113–120
- Novais EN, Kestel LA, Carry PM, Meyers ML. Higher Pavlik harness treatment failure is seen in graf type IV Ortolani-positive hips in males. *Clin Orthop Relat Res*. 2016;474(8):1847–1854

25. Upasani VV, Bomar JD, Matheney TH, et al. Evaluation of brace treatment for infant hip dislocation in a prospective cohort: defining the success rate and variables associated with failure. *J Bone Joint Surg Am.* 2016;98(14):1215–1221
26. Ömeroğlu H, Köse N, Akceylan A. Success of Pavlik harness treatment decreases in patients ≥ 4 months and in ultrasonographically dislocated hips in developmental dysplasia of the hip. *Clin Orthop Relat Res.* 2016;474(5):1146–1152
27. Vadillo P, Encinas-Ullan CA, Moraleda L, Albiñana J. Results of the Pavlik harness when treating Ortolani-positive hips: predictors of failure and arthrographic findings. *J Child Orthop.* 2015;9(4):249–253
28. Sankar WN, Nduaguba A, Flynn JM. Ilfeld abduction orthosis is an effective second-line treatment after failure of Pavlik harness for infants with developmental dysplasia of the hip. *J Bone Joint Surg Am.* 2015;97(4):292–297
29. Murnaghan ML, Browne RH, Sucato DJ, Birch J. Femoral nerve palsy in Pavlik harness treatment for developmental dysplasia of the hip. *J Bone Joint Surg Am.* 2011;93(5):493–499
30. Novais EN, Sanders J, Kestel LA, Carry PM, Meyers ML. Graf type-IV hips have a higher risk of residual acetabular dysplasia at 1 year of age following successful Pavlik harness treatment for developmental hip dysplasia. *J Pediatr Orthop.* 2018;38(10):498–502
31. Allington NJ. Successful Pavlik harness treatment for developmental dysplasia of the hip and normal x-ray at the age of 2 years: is a longer follow-up necessary? *J Pediatr Orthop.* 2017;37(5):328–331
32. Race C, Herring JA. Congenital dislocation of the hip: an evaluation of closed reduction. *J Pediatr Orthop.* 1983;3(2):166–172
33. Sankar WN, Gornitzky AL, Clarke NM, et al; International Hip Dysplasia Institute. Closed reduction for developmental dysplasia of the hip: early-term results from a prospective, multicenter cohort [published online ahead of print November 11, 2016]. *J Pediatr Orthop.* doi:10.1097/BPO.0000000000000895
34. Clarke NM, Jowett AJ, Parker L. The surgical treatment of established congenital dislocation of the hip: results of surgery after planned delayed intervention following the appearance of the capital femoral ossific nucleus. *J Pediatr Orthop.* 2005;25(4):434–439
35. Segal LS, Boal DK, Borthwick L, Clark MW, Localio AR, Schwenker EP. Avascular necrosis after treatment of DDH: the protective influence of the ossific nucleus. *J Pediatr Orthop.* 1999;19(2):177–184
36. Sllamniku S, Bytyqi C, Murtezani A, Haxhija EQ. Correlation between avascular necrosis and the presence of the ossific nucleus when treating developmental dysplasia of the hip. *J Child Orthop.* 2013;7(6):501–505
37. Roposch A, Odeh O, Doria AS, Wedge JH. The presence of an ossific nucleus does not protect against osteonecrosis after treatment of developmental dysplasia of the hip. *Clin Orthop Relat Res.* 2011;469(10):2838–2845
38. Chen C, Doyle S, Green D, et al. Presence of the ossific nucleus and risk of osteonecrosis in the treatment of developmental dysplasia of the hip: a meta-analysis of cohort and case-control studies. *J Bone Joint Surg Am.* 2017;99(9):760–767
39. Sucato DJ, De La Rocha A, Lau K, Ramo BA. Overhead Bryant's traction does not improve the success of closed reduction or limit AVN in developmental dysplasia of the hip. *J Pediatr Orthop.* 2017;37(2):e108–e113
40. Schur MD, Lee C, Arkader A, Catalano A, Choi PD. Risk factors for avascular necrosis after closed reduction for developmental dysplasia of the hip. *J Child Orthop.* 2016;10(3):185–192
41. Gornitzky AL, Georgiadis AG, Seeley MA, Horn BD, Sankar WN. Does perfusion MRI after closed reduction of developmental dysplasia of the hip reduce the incidence of avascular necrosis? *Clin Orthop Relat Res.* 2016;474(5):1153–1165
42. Novais EN, Hill MK, Carry PM, Heyn PC. Is age or surgical approach associated with osteonecrosis in patients with developmental dysplasia of the hip? A meta-analysis. *Clin Orthop Relat Res.* 2016;474(5):1166–1177
43. Schoenecker PL, Strecker WB. Congenital dislocation of the hip in children. Comparison of the effects of femoral shortening and of skeletal traction in treatment. *J Bone Joint Surg Am.* 1984;66(1):21–27
44. Ning B, Yuan Y, Yao J, Zhang S, Sun J. Analyses of outcomes of one-stage operation for treatment of late-diagnosed developmental dislocation of the hip: 864 hips followed for 3.2 to 8.9 years. *BMC Musculoskelet Disord.* 2014;15:401
45. Yagmurcu MF, Bayhan IA, Tuhanioglu U, Kilinc AS, Karakas ES. Clinical and radiological outcomes are correlated with the age of the child in single-stage surgical treatment of developmental dysplasia of the hip. *Acta Orthop Belg.* 2013;79(2):159–165
46. Brougham DI, Broughton NS, Cole WG, Menelaus MB. The predictability of acetabular development after closed reduction for congenital dislocation of the hip. *J Bone Joint Surg Br.* 1988;70(5):733–736
47. Al-Ghamdi A, Rendon JS, Al-Faya F, Saran N, Benaroch T, Hamdy RC. Dega osteotomy for the correction of acetabular dysplasia of the hip: a radiographic review of 21 cases. *J Pediatr Orthop.* 2012;32(2):113–120
48. Karlen JW, Skaggs DL, Ramachandran M, Kay RM. The Dega osteotomy: a versatile osteotomy in the treatment of developmental and neuromuscular hip pathology. *J Pediatr Orthop.* 2009;29(7):676–682
49. Wang CW, Wang TM, Wu KW, Huang SC, Kuo KN. The comparative, long-term effect of the Salter osteotomy and Pemberton acetabuloplasty on pelvic height, scoliosis and functional outcome. *Bone Joint J.* 2016;98-B(8):1145–1150
50. Wang CW, Wu KW, Wang TM, Huang SC, Kuo KN. Comparison of acetabular anterior coverage after Salter osteotomy and Pemberton acetabuloplasty: a long-term followup. *Clin Orthop Relat Res.* 2014;472(3):1001–1009
51. Matheney T, Kim YJ, Zurakowski D, Matero C, Millis M. Intermediate to long-term results following the Bernese periacetabular osteotomy and predictors of clinical outcome: surgical

- technique. *J Bone Joint Surg Am.* 2010;92(suppl 1, pt 2):115–129
52. Cunningham T, Jessel R, Zurakowski D, Millis MB, Kim YJ. Delayed gadolinium-enhanced magnetic resonance imaging of cartilage to predict early failure of Bernese periacetabular osteotomy for hip dysplasia. *J Bone Joint Surg Am.* 2006;88(7):1540–1548
 53. Kim SD, Jessel R, Zurakowski D, Millis MB, Kim YJ. Anterior delayed gadolinium-enhanced MRI of cartilage values predict joint failure after periacetabular osteotomy. *Clin Orthop Relat Res.* 2012;470(12):3332–3341
 54. Clohisy JC, Ackerman J, Baca G, et al. Patient-reported outcomes of periacetabular osteotomy from the prospective ANCHOR cohort study. *J Bone Joint Surg Am.* 2017;99(1):33–41
 55. Grammatopoulos G, Wales J, Kothari A, Gill HS, Wainwright A, Theologis T. What is the early/mid-term survivorship and functional outcome after Bernese periacetabular osteotomy in a pediatric surgeon practice? *Clin Orthop Relat Res.* 2016;474(5):1216–1223
 56. Wells J, Schoenecker P, Duncan S, Goss CW, Thomason K, Clohisy JC. Intermediate-term hip survivorship and patient-reported outcomes of periacetabular osteotomy: the Washington University experience. *J Bone Joint Surg Am.* 2018;100(3):218–225
 57. Lerch TD, Steppacher SD, Liechti EF, Tannast M, Siebenrock KA. One-third of hips after periacetabular osteotomy survive 30 years with good clinical results, no progression of arthritis, or conversion to THA. *Clin Orthop Relat Res.* 2017;475(4):1154–1168

Developmental Dysplasia of the Hip

Scott Yang, Natalie Zusman, Elizabeth Lieberman and Rachel Y. Goldstein
Pediatrics 2019;143;

DOI: 10.1542/peds.2018-1147 originally published online December 26, 2018;

Updated Information & Services

including high resolution figures, can be found at:
<http://pediatrics.aappublications.org/content/143/1/e20181147>

References

This article cites 54 articles, 13 of which you can access for free at:
<http://pediatrics.aappublications.org/content/143/1/e20181147#BIBL>

Subspecialty Collections

This article, along with others on similar topics, appears in the following collection(s):
Orthopaedic Medicine
http://www.aappublications.org/cgi/collection/orthopedic_medicine_sub

Permissions & Licensing

Information about reproducing this article in parts (figures, tables) or in its entirety can be found online at:
<http://www.aappublications.org/site/misc/Permissions.xhtml>

Reprints

Information about ordering reprints can be found online:
<http://www.aappublications.org/site/misc/reprints.xhtml>

American Academy of Pediatrics

DEDICATED TO THE HEALTH OF ALL CHILDREN™



PEDIATRICS®

OFFICIAL JOURNAL OF THE AMERICAN ACADEMY OF PEDIATRICS

Developmental Dysplasia of the Hip

Scott Yang, Natalie Zusman, Elizabeth Lieberman and Rachel Y. Goldstein

Pediatrics 2019;143;

DOI: 10.1542/peds.2018-1147 originally published online December 26, 2018;

The online version of this article, along with updated information and services, is located on the World Wide Web at:

<http://pediatrics.aappublications.org/content/143/1/e20181147>

Pediatrics is the official journal of the American Academy of Pediatrics. A monthly publication, it has been published continuously since 1948. Pediatrics is owned, published, and trademarked by the American Academy of Pediatrics, 141 Northwest Point Boulevard, Elk Grove Village, Illinois, 60007. Copyright © 2019 by the American Academy of Pediatrics. All rights reserved. Print ISSN: 1073-0397.

American Academy of Pediatrics

DEDICATED TO THE HEALTH OF ALL CHILDREN™

