

PediatricsⁱⁿReview[®]

Vertigo

Daune L. MacGregor

Pediatr. Rev. 2002;23;10-16

DOI: 10.1542/pir.23-1-10

The online version of this article, along with updated information and services, is located on the World Wide Web at:

<http://pedsinreview.aappublications.org/cgi/content/full/23/1/10>

Pediatrics in Review is the official journal of the American Academy of Pediatrics. A monthly publication, it has been published continuously since 1979. Pediatrics in Review is owned, published, and trademarked by the American Academy of Pediatrics, 141 Northwest Point Boulevard, Elk Grove Village, Illinois, 60007. Copyright © 2002 by the American Academy of Pediatrics. All rights reserved. Print ISSN: 0191-9601. Online ISSN: 1526-3347.

American Academy of Pediatrics

DEDICATED TO THE HEALTH OF ALL CHILDREN™



Vertigo

Daune L. MacGregor,
MD*

Objectives After completing this article, readers should be able to:

1. Describe the pathophysiologic processes that result in vertigo.
2. Delineate which aspects of the general and neurologic examination are particularly important in diagnosing vertigo.
3. Determine which presentations of vertigo with hearing loss or associated neurologic symptoms require referral to an otolaryngologist for vestibular function testing.
4. Describe appropriate management of vertigo.

Definitions

“Dizziness” is a common complaint that implies a sense of disorientation, usually an altered perception of position in the environment. It may be due to lightheadedness or faintness (eg, the adolescent who has orthostatic hypotension), occur in association with a variety of acute medical disorders (eg, the febrile child who has vomiting and dehydration), or have a psychosomatic origin (eg, depression, anxiety, or exhaustion).

Dizziness is formally classified into four categories: vertigo, presyncope, dysequilibrium, and light-headedness. Vertigo is defined as an illusion of movement, most often a sensation of rotation or, less frequently, linear displacement or tilt. Vertigo is the key symptom of vestibular pathology and usually the result of abnormalities of the labyrinth, although it also may be symptomatic of other neurologic disease (eg, seizures or migraines). It typically is accompanied by symptoms of varying degree, including nausea, vomiting, pallor, and perspiration. There is no loss of consciousness.

Epidemiology

The prevalence of vertigo in children is unknown. A recently published study of Scottish school children reported that 15% had experienced at least one episode of dizziness in a 1-year period. Almost 50% were assessed as having “paroxysmal vertigo” with accompanying symptoms frequently suggestive of migraine (pallor, nausea, phonophobia, and photophobia).

Pathogenesis and Etiology

The etiology of vertigo may be due to abnormalities of the vestibular, visual, or proprioceptive systems. The labyrinth (the paired organs of equilibrium) consists of three semicircular canals stimulated by angular acceleration and the utricle and saccule stimulated by gravitational forces and vertical acceleration. Impulses pass via the vestibular nerve to the vestibular nuclei in the brainstem and then ascend in the medial longitudinal fasciculus (to the cranial nerves for eye movement) and descend in the vestibulospinal tracts (excitatory stimuli to the extensor muscles of the head, extremities, and trunk for maintenance of upright posture). The cerebellum receives afferent impulses and functions as a center for integrating oculovestibular and postural responses. Cortical vestibular representation is at the level of the posterior temporal gyrus.

Vestibular function is assessed by evaluating the oculovestibular reflex and intensity of nystagmus produced by rotatory and caloric stimulation of the labyrinth. The oculovestibular reflex permits ocular fixation on stationary objects while the head and body are in motion.

*Professor of Paediatrics (Neurology), Clinical Director, Division of Neurology, Department of Paediatrics, Hospital for Sick Children, University of Toronto, Toronto, Ontario, Canada.

Nystagmus is the observed movement of the eye in response to stimulation of the labyrinth, retro-cochlear vestibular, or central vestibulo-ocular pathway. It is classified as spontaneous or induced by direction and by fatigability. The direction of nystagmus is designated by the fast component (ocular realignment). The slow component represents the oculovestibular response.

Vertigo may be due to peripheral vestibular disease or central vestibular dysfunction. When not associated with actual movement, the cause of vertigo is found in the peripheral system in 85% of cases. Use of the term “peripheral” implies that the problem occurs either in the end organ (semicircular canals or utricle) or in the peripheral nerve.

The clinical presentations differ and allow for localization of the vertiginous symptomatology (Table 1).

Clinical Aspects

The medical history is the initial and most important step in evaluation of the child who complains of dizziness or vertigo. Young children may not have the capacity or vocabulary to describe the sensation of vertigo, but they can use “playground synonyms” such as spinning, swinging, sliding, or like “a merry-go-round.” The key symptom is a sensation of motion that is either rotatory or linear.

The associated aural and neurologic symptoms must be sought carefully. Are there other symptoms of hearing loss (that may fluctuate), fullness, pressure, or ringing? Is there objective evidence of a hearing disorder? If tinnitus or ringing is present, is it continuous, intermittent, or pausatile? Are there symptoms of cortical or brainstem disorders such as headache, visual changes, seizures, or loss of consciousness?

Physical Examination

The complete physical examination should focus on neurologic evaluation of the cranial nerves and cerebellar function (past-pointing and tandem gait). The auditory canal and tympanic membranes must be examined to evaluate for evidence of middle ear infection, malformations, cholesteatoma, or a perilymphatic fistula. A fistula test can be performed in a cooperative child with a pneumatic otoscope or tragal pressure. The child is instructed to look straight ahead, and the eyes are exam-

Table 1. Clinical Presentations of Vertigo

	Peripheral	Central
Occurrence	Episodic, sudden onset	Constant
Direction of spinning/ nystagmus	Unidirectional	Variable
Nystagmus axis	Horizontal, rotary	Horizontal, vertical, oblique, or rotary
Nystagmus type	Slow and fast phase	Irregular or equal phase
Hearing loss, tinnitus	Possible	No
Loss of consciousness	No	Possible
Other neurologic signs/ symptoms	No	Cranial nerve deficits, cerebellar and pyramidal signs frequent

Modified from Cohen NL. *Med Clin North Am.* 1991;75:1251–1260.

ined while continuous positive and then negative pressure is applied. Normally, there should be no drift of the eyes. In the presence of perilymphatic fistula, the eyes may drift slowly away from the ear with positive pressure and back toward the ear with negative pressure.

An important sign is the presence of spontaneous or induced nystagmus. Endpoint or physiologic nystagmus is seen in normal children at a 40-degree deviation of the eyes. Because visual fixation may inhibit mild vestibular nystagmus, otolaryngologists use Frenzel glasses (+10 diopters) both to magnify the eyes and to prevent fixation suppression.

Balance Testing

Clinical testing in the office or emergency department may provide much information about the child or adolescent who has vertigo. Simple tests of balance include the Romberg and Unterberger-Fukuda test (stepping or marching test). The Romberg test evaluates proprioceptive function. A variation of the original examination—the tandem Romberg test—can be performed by having the child place one foot directly in front of the other with the arms either at the sides or crossed in front. Vision is allowed and then excluded. The Unterberger-Fukuda test is performed with the arms placed straight out in front at shoulder height. Vision is excluded, and the child is instructed to maintain the original position and march in place. A total of 50 marching steps should be taken. Normally, patients either will remain in place, step forward up to 50 cms, or turn within approximately 30 degrees of center. Patients who have chronic peripheral vestibular lesions will march slowly toward the side of the lesion.

The Hallpike-Dix maneuver should be used during the neurologic examination to elicit paroxysmal positional nystagmus. The child is placed in a sitting position

midway on a flat examining table and instructed to look straight ahead at all times. The examiner first turns the head to the side, and the patient then quickly is placed backwards with the head over the end of the table. The response in patients who have a positional vertigo is horizontal rotary nystagmus with the fast phase to the downward ear. The onset of the nystagmus is delayed with typically a 1- to 2-second latency that lasts for 10 to 20 seconds and is associated with a sensation of rotational vertigo. With this positioning maneuver, nystagmus and vertigo occur with the affected ear down. If a diagnosis of benign paroxysmal positional vertigo is considered clinically, the Hallpike-Dix maneuver is not recommended because it may interfere with immediate bedside treatment of this disorder.

Laboratory Testing

All patients who have symptoms of vertigo must undergo hearing testing or, in infants, auditory brainstem evoked response testing. Additional pediatric investigations depend on the characteristics of the vertigo and accompanying symptoms in the individual patient. Children who have persistent nonspecific vertigo require a complete blood count, glucose tolerance test, and measurement of electrolytes, calcium, phosphorous, magnesium, and thyroid function. Certain patients may require testing for sickle cell disease. Patients who have sensorineural hearing loss or neurologic findings should receive computed tomography with thin cuts through the temporal bones, magnetic resonance imaging (\pm gadolinium), or angiography. If there is a history of associated loss of consciousness, an electroencephalographic study should be obtained.

Special Vestibular Function Testing

Based on the course of the symptoms, the physical examination, and the results of the previously noted investigations, the child may require referral to an otolaryngologist for additional vestibular testing. Caloric testing is the definitive procedure for identification of vestibular pathology. Electronystagmography is a collection of examinations for the saccadic, optokinetic, and smooth pursuit systems and of nystagmus induced by warming and cooling the labyrinth. These tests are nonspecific and do not provide a diagnosis, but when results are abnormal, they are suggestive of vestibular dysfunction.

Table 2. Acute Paroxysmal Vertigo

Hearing Loss	No Hearing Loss
<ul style="list-style-type: none"> • Labyrinthitis • Menière disease • Perilymphatic fistula • Vascular occlusion • Temporal bone fracture 	<ul style="list-style-type: none"> • Infants—benign paroxysmal vertigo or torticollis • Adolescents—vestibular neuronitis • Labyrinthine concussion • Paroxysmal positional vertigo • Migraine • Seizures • Subclavian steal

Modified from Eviatar L. *Otolaryngol Clin North Am.* 1994;27:557–571.

Other testing used by otolaryngologists in specific circumstances includes rotating chair tests, vestibular autorotation test (physiologic stimuli of high frequency produced by active head oscillations), and posturography (sway movement testing).

Diagnostic Approach and Specific Common Disorders

Acute-onset vertigo or paroxysmal episodes of vertigo can be approached clinically based on the presence or absence of hearing loss (Table 2). If vertigo is continuous and unremitting, assessment can be based on the presence or absence of neurologic abnormalities (Table 3).

Acute Paroxysmal Vertigo With Hearing Loss

LABYRINTHITIS. The diagnosis of labyrinthitis is based on a history of infection preceding the onset of vertigo and the presence of hearing impairment. The child usually is most comfortable lying on the unaffected side. Any movement causes severe vertigo, nausea, and vomiting. These episodic symptoms usually subside after several days.

PERILYMPHATIC FISTULA. This condition is much more frequent in children than had been recognized in the past and often is caused by minor head trauma. There is a sudden onset of hearing loss and vertigo from rupture of the round or oval window into the vestibule that results in the creation of a fistula. An abrupt change in barometric pressure (eg, decompression syndrome) also can result in a similar rupture.

MENIÈRE DISEASE. Menière syndrome is very uncommon in children. Symptoms consist of vertigo, fluctuating hearing loss, a sensation of pressure in the ear, and tinnitus. Recurrent episodes of vertigo and tinnitus are common, with progressive hearing loss after each event.

Table 3. Continuous Vertigo

Neurologic Abnormalities	No Neurologic Abnormalities
<ul style="list-style-type: none"> • Acoustic neuroma (neurofibromatosis type II) • Posterior fossa tumour • Drug-induced* • Cholesteatoma • Cerebral infarction • Demyelinating disease (multiple sclerosis or central nervous system Lyme disease) • Vertebrobasilar insufficiency 	<ul style="list-style-type: none"> • Metabolic disease** • Tension-type headache • Panic and anxiety disease • Depression • Severe anemia • Sickle cell disease • Polycythemia • Hyperviscosity syndromes • Cardiac dysrhythmias

*Aminoglycosides, ethacrynic acid, furosemide, isoniazid, quinine, acetylsalicylic acid, diphenylhydantoin

**Diabetes mellitus, endocrine disorders (Addison disease, thyroid disease)

Modified from Eviatar L. *Otolaryngol Clin North Am.* 1994;27:557–571.

Acute Paroxysmal Vertigo Without Hearing Loss

VESTIBULAR NEURONITIS. This disorder primarily occurs in adolescents following respiratory infection. Symptoms include vertigo, nausea, and vomiting with postural instability. Episodes are self-limited but tend to recur with decreasing intensity. Diagnosis is made by electronystagmography and thermal caloric testing.

BENIGN PAROXYSMAL VERTIGO AND TORTICOLLIS.

Benign paroxysmal vertigo presents initially between 1 and 2 years of age, with symptoms recurring to the age of 4 years. The child presents suddenly with extreme unsteadiness and may be unable to remain upright. Nystagmus may be present, but other symptoms such as vomiting are uncommon. The child is fully conscious throughout the entire episode. Many children develop migraine later in life. The diagnosis is supported by a family history of migraine.

Another migraine variant seen in infants is paroxysmal torticollis. A child who has this rare form of migraine will tilt his or her head to one side for several hours (and infrequently for up to several days). There may be associated vomiting. These episodes usually cease by 2 years of age, with many children developing typical migraine headaches by early childhood.

LABYRINTHINE CONCUSSION. Head trauma with or without temporal bone fracture can produce labyrinthine concussion. There is severe vertigo, with unsteadiness and falling toward the affected side. These symptoms may persist, but they gradually diminish in intensity over a 4- to 6-week period.

BENIGN PAROXYSMAL POSITIONAL VERTIGO.

Benign paroxysmal positional vertigo has been described in children as young as 11 years of age. The cause has been determined to be the presence of free-floating debris in the posterior semicircular canal. This type of vertigo has been related to head trauma or vestibular neuronitis. In a proportion of patients, no cause can be found. Benign paroxysmal positional vertigo is provoked by a change in position and lasts for seconds.

MIGRAINE AND SEIZURES.

Basilar artery migraine presents primarily in adolescent girls with recurrent stereotypic attacks of brainstem and cerebellar dysfunction. The clinical features can include ataxia, dysarthria, vertigo, and tinnitus. There are variable bilateral visual complaints. Alternating hemiplegia and paresthesias of the face and limbs can occur, and there can be alteration of consciousness. A severe pounding or pulsatile headache will follow.

Vertigo also may be the aura preceding a generalized seizure or present as an actual ictal phenomenon (partial complex seizure). Vestibulogenic seizures are very rare and represent a form of reflex sensory epilepsy (induced by spinning).

Management and Prognosis

The treatment of vertigo depends on the duration and discomfort of the symptom and the underlying pathology. Acute vertigo can be treated symptomatically and with reassurance. Antiemetics can be given rectally or intramuscularly. Vestibular sedation or suppressant medication is also useful (meclizine, dimenhydrinate, promethazine, and diazepam). Persistent severe nausea and vomiting may require administration of prochlorperazine or metoclopramide.

Most children who have acute vertigo recover spontaneously over a period of several weeks to months. Symptomatic recovery is due to vestibular compensation and central plasticity (reorganization of vestibular circuits). In some children and adolescents, symptoms recur, often in association with physical or psychological stress. Medications producing vestibular sedation should not be prescribed for long-term daily use be-

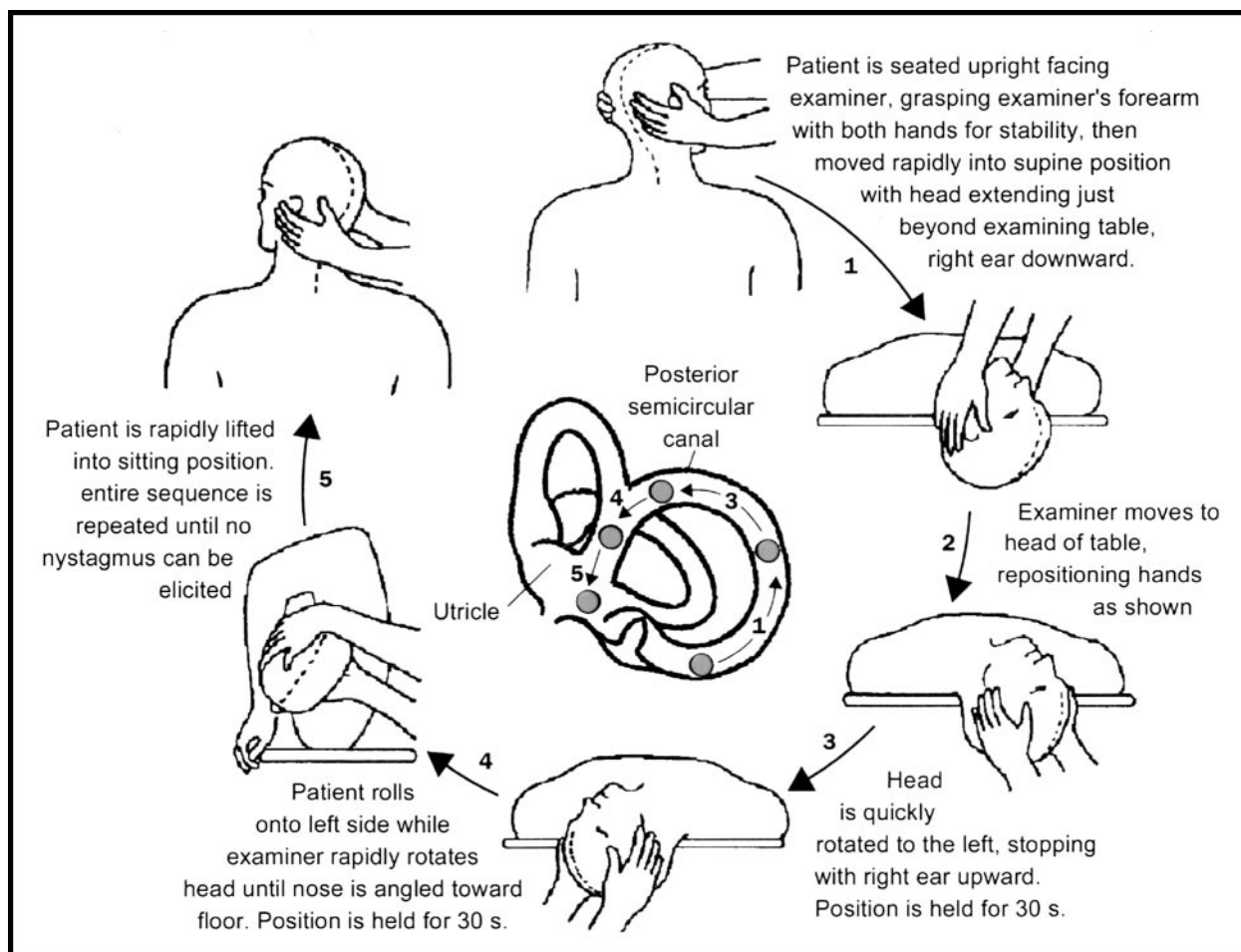


Figure. Epley particle repositioning maneuver.

cause they may interfere with the normal compensation process.

A specific treatment for benign paroxysmal positional vertigo is a bedside maneuver (Epley particle repositioning maneuver). This maneuver relocates the free floating debris from the posterior semicircular canal into the vestibule of the labyrinth. Symptomatic relief after a single treatment session is reported in 80% to 90% of patients, although 15% to 30% may have recurrence of symptoms. The maneuver is repeated until nystagmus no longer can be elicited (Figure). A modified version of the Epley maneuver can be taught to patients with instructions to perform the activity three times a day until there are no symptoms of positional vertigo for 24 hours.

Chronic or recurrent vertigo is often resistant to treatment, but it may respond to a course of clonazepam or carbamazepine. Exercise regimens also have been pre-

scribed, with balance and gait training during dynamic tasks that precipitate the patient's symptoms. These exercises are practiced until an asymptomatic state is reached. Management of accompanying psychological symptoms (eg, anxiety, panic attacks, depression) depends on the nature of the associated symptom.

Surgical procedures for the treatment of vertigo rarely are required in childhood. Endolymphatic arachnoid shunt operations are successful in 65% of patients who have Menière disease. Disabling vertigo due to vestibular nerve or labyrinthine disorders may require vestibular nerve section. Surgery is an option for patients who have severe intractable benign paroxysmal positional vertigo using procedures to disable the posterior semicircular canal.

Appropriate management of vertigo depends on determination of the etiology and carefully tailored treat-

ment plans specific to the vestibular or central disorder producing the vertigo.

Suggested Reading

- Baloh RW. Vertigo. *Lancet*. 1998;352:1841–1846
- Cohen NL. The dizzy patient: update on vestibular disorders. *Med Clin North Am*. 1991;75:1251–1260
- Derebery MJ. The diagnosis and treatment of dizziness. *Med Clin North Am*. 1999;83:163–177
- Eviator L. Dizziness in children. *Otolaryngol Clin North Am*. 1994;27:557–571
- Fife TD, Tusa RJ, Furman DS, et al. Vestibular testing techniques in adults and children. *Neurology*. 2000;55:1431–1441
- Furman JM, Cass SP. Benign paroxysmal positional vertigo. *N Engl J Med*. 1999;341:1590–1596
- Linstrom CJ. Office management of the dizzy patient. *Otolaryngol Clin North Am*. 1992;25:745–780
- Luxon LM. Vertigo. New approaches to diagnosis and management. *Br J Hosp Med*. 56:519–520, 537–543
- Russell G, Abu-Arafeh I. Paroxysmal vertigo in children—an epidemiological study. *International J Ped Otorhin*. 1999;49:S105–S107

PIR Quiz

Quiz also available online at www.pedsinreview.org.

5. A 12-year-old child complains of dizziness and a feeling of the room "spinning around him" for the past 12 hours. He has had a cough and runny nose for 3 days. The symptoms improve when he lies on the left side and worsen when he attempts to move from one place to another. Physical examination shows an intact sensorium. Fundusoscopic examination results are normal, and external ocular movements are intact. Tympanic membranes are normal. Sense of position and vibration and deep tendon reflexes are normal. Hearing is impaired in the right ear. No tremors are noted, and finger-to-nose test results are normal. Which of the following structures is *most* likely to be affected?
 - A. Cerebellum.
 - B. Labyrinth.
 - C. Midbrain.
 - D. Optic nerves.
 - E. Posterior columns.
6. A previously well 2-year-old child presents with marked unsteadiness for the past 12 hours. He now is unable to stand or walk. There is no history of vomiting, and the child otherwise appears well. His mother has had episodes of migraine for several years. Physical examination reveals no abnormalities other than extremely unsteady gait and posture. Which of the following is the *most* likely diagnosis?
 - A. Benign paroxysmal vertigo.
 - B. Cerebellitis.
 - C. Guillain-Barré syndrome
 - D. Medulloblastoma.
 - E. Transverse myelitis.
7. A 5-year-old boy presents with a 2-week history of unsteady gait. He has had early morning headaches for the past 3 months. He often complains of double vision, and his mother notes that he seems to bump into objects while walking. For the past week, he has been drooling and appears to have difficulty swallowing. Physical examination shows mild left-sided facial weakness and weakness of the extremities. Which of the following is the *most* appropriate next step in management?
 - A. Brain stem evoked potentials.
 - B. Epley particle positioning maneuver.
 - C. Lumbar puncture.
 - D. Magnetic resonance imaging of the brain.
 - E. Test for visual refraction errors.
8. A 12-year-old boy presents with a feeling of dizziness and a sensation of objects spinning around him for 1 day. He also complains of hearing loss in the right ear. The symptoms started shortly after he was struck by a baseball during a game. Physical examination shows normal ear canals and tympanic membranes. Pneumatic otoscopy of the right ear reveals drifting of the eyes to the left with positive pressure and drifting back to the right with negative pressure. Which of the following is the *most* likely diagnosis?
 - A. Benign paroxysmal positional vertigo.
 - B. Epidural hematoma.
 - C. Lateral sinus thrombosis.
 - D. Menière syndrome.
 - E. Perilymphatic fistula.

Vertigo
Daune L. MacGregor
Pediatr. Rev. 2002;23;10-16
DOI: 10.1542/pir.23-1-10

**Updated Information
& Services**

including high-resolution figures, can be found at:
<http://pedsinreview.aappublications.org/cgi/content/full/23/1/10>

Permissions & Licensing

Information about reproducing this article in parts (figures,
tables) or in its entirety can be found online at:
<http://pedsinreview.aappublications.org/misc/Permissions.shtml>

Reprints

Information about ordering reprints can be found online:
<http://pedsinreview.aappublications.org/misc/reprints.shtml>

American Academy of Pediatrics

DEDICATED TO THE HEALTH OF ALL CHILDREN™

