

# A practical, simple, and useful method of categorizing interictal EEG features in children

Se Hee Kim, MD  
Christian M. Korff, MD  
Andrew J. Kim, MD  
Douglas R. Nordli, Jr., MD

Correspondence to  
Dr. Nordli:  
dnordli@luriechildrens.org

## ABSTRACT

We introduce a simple scheme of categorizing interictal EEG in patients with pediatric epilepsy. Five patterns of EEG can be determined by using 2 interictal EEG domains: organization of the background activity and a morphology/topography of epileptiform discharges. These patterns relate to commonly recognized categories of pediatric epilepsy: familial epilepsies, genetic generalized epilepsies, self-limited epilepsies, epilepsies with encephalopathy, and focal structural epilepsies. Each group has distinguishable clinical presentations, inheritance patterns, and outcomes. This categorization may be a useful educational tool; it may also guide decisions about further testing and management. *Neurology*® 2015;85:471-478

## GLOSSARY

**AED** = antiepileptic drug; **BCSSS** = benign childhood seizure susceptibility syndrome; **EIEE** = early infantile epileptic encephalopathy; **IED** = interictal epileptiform discharges.

Recent advances in genetics and imaging have expanded our understanding of epilepsy and lead us to more accurate, in-depth diagnoses.<sup>1</sup> For a structured genetic and biologic classification to be built, however, the right groupings of epilepsy phenotypes aided by EEG should be organized.

We introduce a simple scheme of categorizing epilepsy by using interictal EEG. We discuss the relation of this EEG categorization scheme to the current list of electroclinical syndromes. This EEG categorization will be beneficial to neurologists, particularly to new learners of EEG, because of its simplicity.

**CATEGORIZING EPILEPSY BY INTERICTAL EEG** At a minimum, all that is required is one interictal EEG that accurately represents the baseline cerebral activity of the patient, recorded during sleep and wakefulness. A brief 30-minute routine EEG is usually sufficient, but EEG is subject to sampling errors, and sometimes multiple EEGs are required to capture interictal epileptiform discharges (IED). In each EEG, 2 domains are evaluated: (1) organization and slowing of the background activity and (2) a morphology/topography of epileptiform discharges. The organization of the background refers to the anterior to posterior voltage and frequency gradient, as well as the frequency of the different key rhythms, such as the posterior dominant rhythm, frontal  $\beta$  activity, and central rhythms. The morphology of the epileptiform activity focuses on the degree to which the epileptiform discharges are stereotyped or polymorphic.

Five commonly seen EEG patterns can be identified based on the combination of the 2 EEG features. The patterns correlate with commonly recognized groupings of epilepsy (table 1): (1) familial epilepsies, (2) genetic generalized epilepsies, (3) self-limited epilepsies, (4) epilepsies with encephalopathy, and (5) focal structural epilepsies. They can be readily identified by their clinical presentation and interictal EEG.

**Pattern 1: The familial epilepsies.** A relatively small proportion of children with epilepsy who have consistently normal interictal EEGs belong to this group. The background is well-organized. IED are absent or rarely present. Patients often have a strong family history consistent with an autosomal dominant inheritance.<sup>2-6</sup> Seizures are often focal and a good response to carbamazepine has been reported in many of the associated epilepsies.<sup>7</sup>

**Pattern 2: Genetic generalized spike-wave epilepsies.** In children and adolescents with epilepsy, a common EEG pattern is a combination of a normal background with well-developed regular or stereotyped

From the Department of Pediatrics (S.H.K., A.J.K., D.R.N.), Epilepsy Center, Ann & Robert H. Lurie Children's Hospital of Chicago, and the Northwestern University Feinberg School of Medicine, IL; and Pediatric Neurology (C.M.K.), Child and Adolescent Department, University Hospitals, Geneva, Switzerland.

Go to [Neurology.org](http://Neurology.org) for full disclosures. Funding information and disclosures deemed relevant by the authors, if any, are provided at the end of the article.

**Table 1** Five epilepsy EEG patterns

Pattern	Epilepsy group	EEG background	Interictal epileptiform discharges
1	Familial epilepsies	Normal	None
2	Genetic generalized epilepsies	Normal	Stereotyped generalized
3	Self-limited epilepsies	Normal	Stereotyped focal or multifocal
4a (b) <sup>a</sup>	Epileptogenic encephalopathies	Diffusely slowed (with decrements)	Pleomorphic multifocal and diffuse
5a (b) <sup>a</sup>	Focal structural epilepsies	Focal slowing (with decrements)	Pleomorphic focal

A combination of 2 interictal EEG domains was used: organization of the background activity and a morphology/topography of epileptiform discharges.

<sup>a</sup>Patterns 4 and 5 are subcategorized as 4b and 5b if electrodecrements are present.

generalized spike-wave discharges with repetition rates of 3 Hz or greater (figure 1A). These epilepsies could be called genetic generalized epilepsies because they show generalized spike-wave discharges and have a genetic component, indicated by positive family histories.<sup>8,9</sup> Generally, broad spectrum agents are used and sodium channel drugs are avoided.<sup>10</sup> The prognosis is generally favorable, although some will require treatment for prolonged periods.

**Pattern 3: Self-limited epilepsies with focal spikes.** The commonest forms of pediatric epilepsy show 2 EEG features: normal interictal backgrounds and highly stereotyped spikes (figure 1B). Panayiotopoulos<sup>11</sup> uses the apt term benign childhood seizure susceptibility syndrome (BCSSS) for these conditions. Clinical presentations and the prominent location of the active focus are age-dependent. Spikes tend to be inherited in an autosomal dominant fashion with variable penetrance according to age.<sup>12</sup> The clinical predisposition to epilepsy, however, appears to have a relatively small genetic component, as substantiated by several studies including an analysis of several twin registries.<sup>8,13–17</sup> Outcome is almost always excellent with regard to the cessation of seizures but there may be issues associated with learning, behavior, or attention.<sup>18</sup> Prophylactic treatment is generally avoided.

**Pattern 4: Epilepsies with encephalopathy.** These epilepsies are associated with an encephalopathy and need to be promptly recognized and treated. They share common EEG features: diffuse background slowing and pleomorphic multifocal epileptiform discharges (figure 2A). There may be various contributions of genetic, metabolic, and structural causes in each individual and it is rare to find a familial predisposition to either the EEG features or the epilepsy in these patients. If present, genetic causes in this group are usually de novo mutations.<sup>19–21</sup> There are 2 subtypes of EEGs found in this group. The first group has a continuous, disorganized background. The second group shows a certain degree of discontinuity superimposed on their background activity.

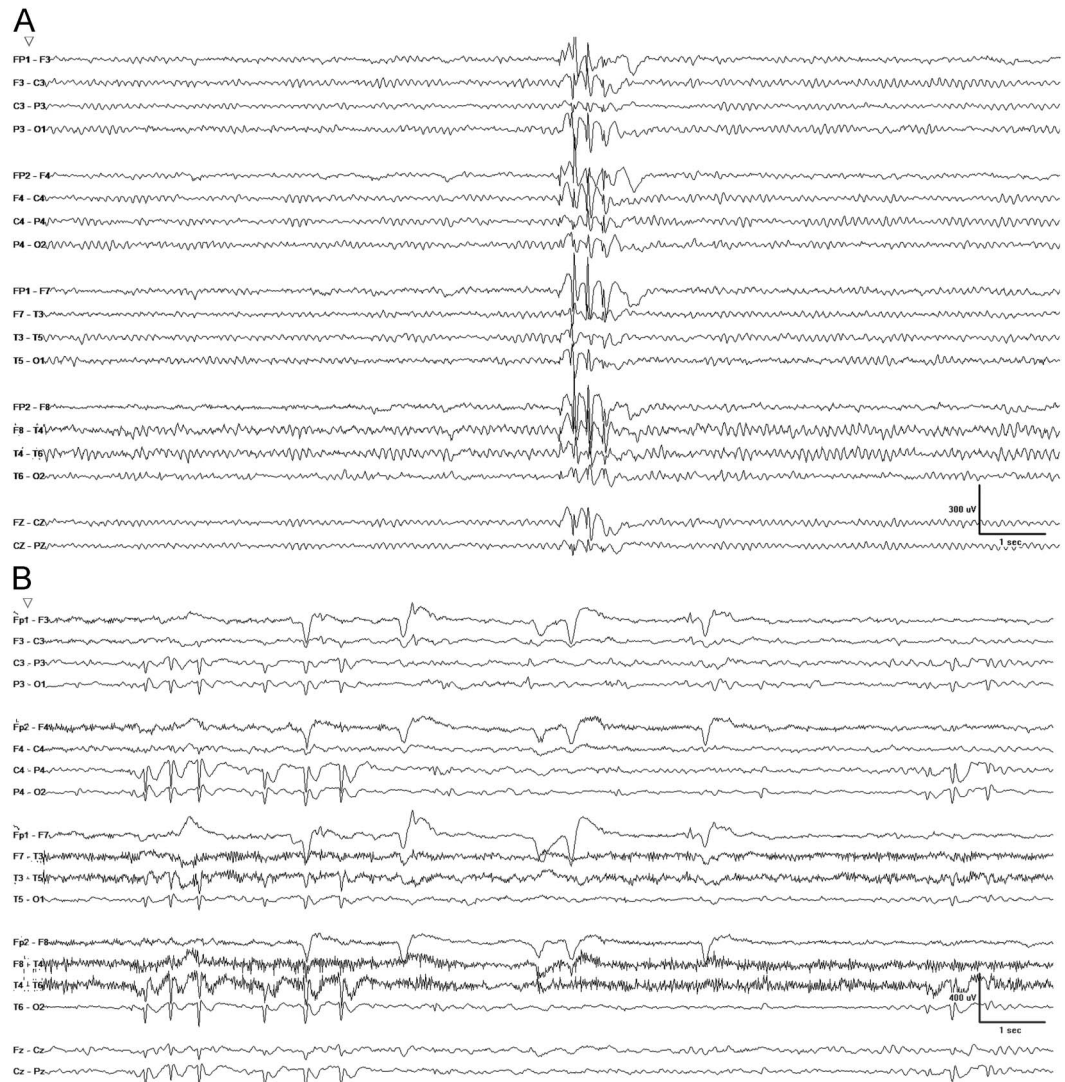
**Epileptogenic encephalopathies.** This group may be called the epileptogenic encephalopathies, meaning that the same factor or factors that produce the encephalopathy also cause the epilepsy. We anticipate some broad themes to emerge in this group in the future, reflective of the underlying pathophysiology. At present, however, this complex group of patients remains poorly characterized. The EEGs by themselves seldom suggest a specific diagnosis. Children in this group often develop intractable epilepsy after failing multiple antiepileptic drugs (AEDs).

**Epileptic encephalopathies.** The term epileptic encephalopathy signifies that the epilepsy per se may contribute to encephalopathy and have urgent treatment implications. Yamatogi and Ohtahara<sup>22</sup> conceptualized a spectrum with age-related differences in clinical and EEG manifestations, but a common thread of severe EEG findings, epileptic encephalopathy, and refractory seizures including tonic spasms. The EEGs show a discontinuous background, electrodecremental responses, or both. These features indicate a susceptibility to epileptic spasms and myoclonic-tonic and generalized tonic seizures.

**Pattern 5: Focal structural epilepsies.** Focal structural lesions, regardless of their nature, are often associated with focal slowing, attenuation, or both. In addition, IED tend to be pleomorphic with variations in their precise morphology and topography. This contrasts with the spikes seen in self-limited epilepsies with focal seizures; in the latter, the spikes tend to be uniform or stereotypic.

**Focal structural epilepsies with spasms.** This category includes epilepsies with focal seizures that are accompanied by epileptic spasms. Currently, it is hard to determine how often epileptic spasms occur in a child with a structural lesion. In one of our studies, however, among 161 participants who had epileptic spasms, we could identify as many as 91 children who did not have typical hypsarrhythmia. In these children, underlying structural lesion on MRI and co-existing focal motor seizures were more common than in patients with West syndrome.<sup>23</sup> A similar trend has

**Figure 1** EEG patterns 2 and 3

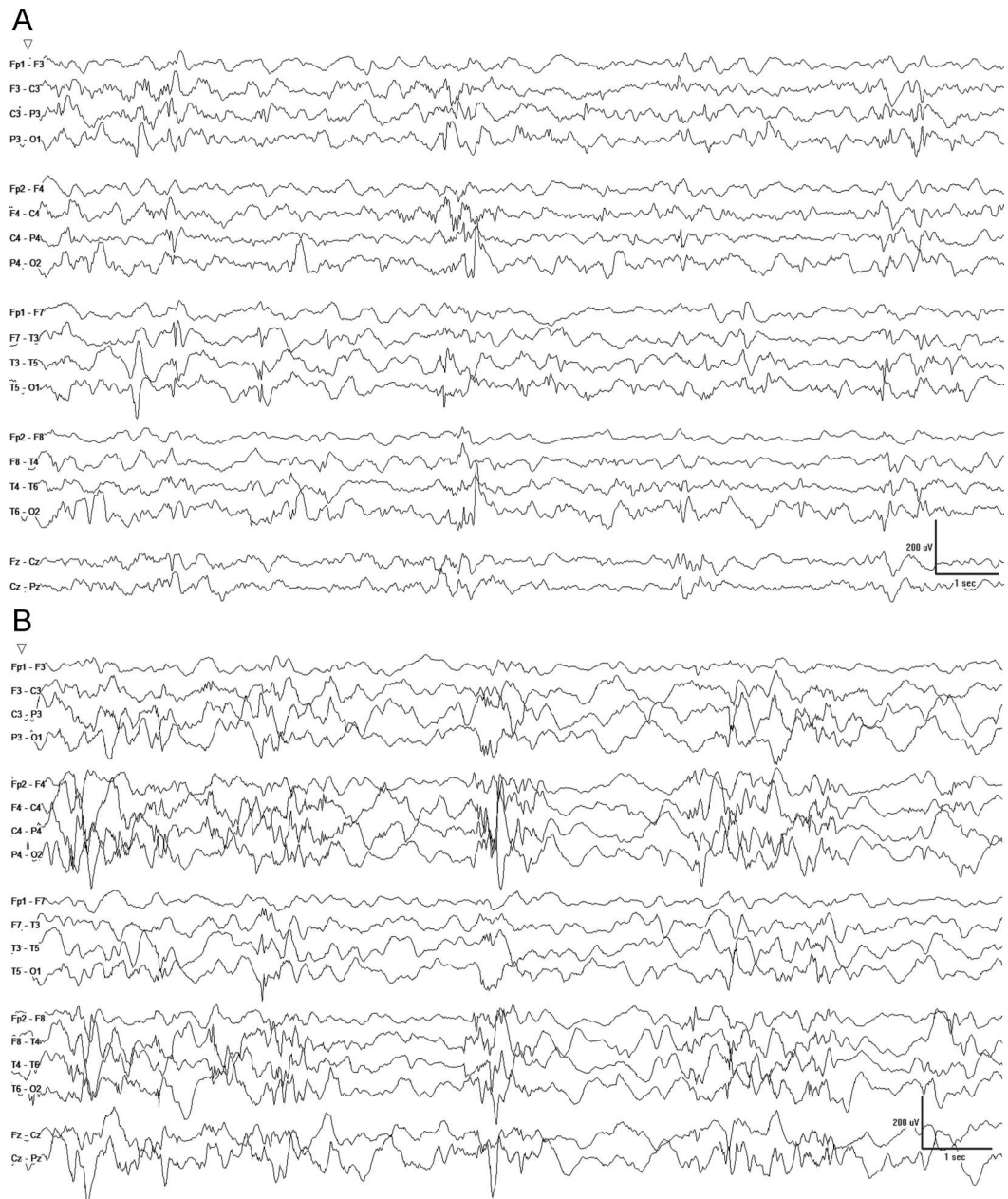


The background is normal and interictal epileptiform discharges are stereotyped. (A) EEG pattern 2. A normal background and stereotyped generalized synchronous spike-waves with frontal accentuation are observed. (B) EEG pattern 3. EEG shows highly stereotyped spike-wave complexes localized in the occipital region. Background EEG is normal.

also been reported by another study.<sup>24</sup> The temporal relationship between epileptic spasms and a focal neocortical lesion has been confirmed by another study by using electrocorticography.<sup>25</sup> In these circumstances, the interictal EEG may show multifocal spikes, electrodecrements, and epoch of discontinuity (figure 2B), just as in epileptic encephalopathies. In some cases, the background may be indistinguishable, but pronounced segments in the form of asymmetric slowing, attenuation, loss of complexity, spike amplitude, and sleep architecture may be valuable clues to the presence of an underlying focal structural lesion. We suspect that epileptic spasms outside of West syndrome, possibly in relation to a structural lesion, are not rare, but are under-recognized. These may require careful inspection of the clinical and EEG features in order to be appreciated.

**A PILOT STUDY AT OUR CENTER** **Methods.** In order to test the feasibility and the clinical utility of categorizing epilepsy by using interictal EEG in children, we conducted a pilot study, retrospectively reviewing initial EEGs of 57 children with epilepsy chosen to illustrate a variety of different epilepsies. We de-identified the EEGs and 2 epileptologists reviewed them blindly (A.J.K. and S.H.K.). Per each EEG, specific IED and background features were evaluated and pattern was determined. Age at onset was analyzed by using Kruskal-Wallis test. Pearson  $\chi^2$  test was performed to see the difference between the groups. In order to characterize each group better, each group was also compared to one combined group of the others. A *p* value less than 0.05 was considered significant. The reliability of classifying EEG patterns was assessed by the kappa





(A) In EEG pattern 4a, the background is diffusely slowed and interictal epileptiform discharges are pleomorphic and multifocal. (B) In EEG pattern 5b, the background is markedly asymmetric. Interictal epileptic discharges are pleomorphic and multifocal, predominant on the right hemisphere. The background activity is frequently interrupted by marked electrodecrements.

statistic to determine interobserver agreement between reviewers beyond chance. A preliminary assessment of outcome was conducted by reviewing the electronic medical records for diagnostic evaluation, treatment, response to medication, and developmental outcome. All subjects had at least 1 year of follow-up from the initial EEG.

**Standard protocol approvals, registrations, and patient consents.** Our institutional review board approved this retrospective study with waiver of informed consent.

**Patient characteristics.** A summary of the patient findings is provided in table 2. The median age of the patients at the onset of seizures was 2 years (maximum = 16, minimum = 2, interquartile range 0–7). Median follow-up duration was 1 year (maximum = 8, minimum = 1, interquartile range 1–2).

**Inter-reviewer reliability.** Among 57 EEGs, the reviewers agreed on 51 (89%) EEGs and disagreed on 6 (11%) by categorizing the EEGs in different EEG groups. Overall, interobserver agreement was high

**Table 2** Characteristics of patients, treatment, and outcome in each EEG pattern group

	Total (n = 57)	1 (n = 6)	2 (n = 8)	3 (n = 6)	4 (n = 20)	5 (n = 17)	p Value
Sex, F:M	30:27	2:4	5:3	5:1	12:8	6:11	0.2
Age at onset, y, median (IQR)	2 (8)	2 (3)	9 (15)	8 (5)	0 (1)	3 (9)	0.01
Abnormal neurologic examination, n (%)	16 (28)	1 (17)	1 (13)	0	6 (30)	8 (47)	0.1
Abnormal development							
Initially, n (%)	18 (32)	1 (17)	0	1 (17)	9 (45)	7 (41)	0.1
At follow-up, n (%)	24 (42)	1 (17)	0	1 (17)	12 (60)	10 (59)	0.01
MRI							
Performed, n (%)	42 (74)	5 (83)	5 (63)	0	17 (85)	15 (88)	<0.0001
Structural lesion, n (%)	23 (55)	2 (40)	1 (20)	0	11 (65)	9 (60)	0.3
Genetic diagnosis, n (%)	6 (11)	0	0	0	6 (30)	0	0.01
Treatment							
Surgery, n (%)	1 (2)	0	0	0	0	1 (6)	0.7
Ketogenic diet, n (%)	9 (16)	0	1 (13)	0	4 (20)	4 (24)	0.5
Antiepileptic drug, n (%)	49 (86)	4 (67)	8 (100)	2 (33)	20 (100)	15 (88)	0.001
Seizure freedom for 1 year							
At last FU, n (%)	30 (53)	6 (100)	4 (50)	5 (83)	7 (35)	8 (47)	0.04
At last FU with no AED, n (%)	14 (25)	2 (33)	1 (13)	5 (83)	1 (5)	5 (29)	0.003

Abbreviations: AED = antiepileptic drug; FU = follow-up; IQR = interquartile range.

( $\kappa = 0.82$ ). EEGs that were categorized differently by the 2 reviewers included the following: (1) 2 EEGs with generalized spike-wave discharges and occipital intermittent rhythmic delta activity, which were finally classified as pattern 2 after the second joint review; (2) 1 EEG with stereotyped bitemporal spikes and unilateral focal slowing, which was later categorized as 5; (3) 1 EEG with focal slowing superimposed on diffusely slowed background, which was categorized as 5; (4) 1 EEG with rare spikes and diffusely slowed background, which was determined to be 4; and (5) 1 EEG with multifocal spikes with left hemisphere background attenuation, which was later classified as 5.

**Follow-up of subjects.** Children who had normal EEG background (pattern 1) were more likely to be seizure-free at the last follow-up than the other groups ( $p = 0.016$ ). Children with EEG pattern 2, stereotyped generalized spike-waves and a normal background, were older than the others ( $p = 0.01$ ) and were likely to show normal development before ( $p = 0.03$ ) or after ( $p = 0.01$ ) the seizure onset. Children who showed stereotyped, focal spikes and normal background (pattern 3) were not likely to receive a MRI study ( $p < 0.0001$ ), or to be treated with an AED ( $p < 0.0001$ ), but still had the most favorable outcome compared to the others ( $p < 0.0001$ ). Children who showed multifocal pleomorphic spikes and slow background on EEG (pattern 4) were

more likely to have an earlier seizure onset ( $p = 0.01$ ) and a confirmed genetic diagnosis by conventional genetic tests ( $p < 0.0001$ ), most likely to be treated with an AED ( $p = 0.029$ ), and least likely to be seizure-free on no AEDs ( $p = 0.012$ ). Genetic diagnoses of the patients with EEG pattern 4 included trisomy 21 in 2 patients, *TSC* gene mutation in 2, *CDKL5* gene mutation in 1, and a *SHOX* gene mutation in 1. Children who showed focal pleomorphic spikes and slowing on EEG (pattern 5) were more likely to show abnormal neurologic examination than the others ( $p = 0.04$ ).

**RELATION WITH THE CURRENT INTERNATIONAL LEAGUE AGAINST EPILEPSY SYNDROME DIAGNOSIS** We attempted to apply the findings of the International League Against Epilepsy report from 2010<sup>26</sup> to our system (figure 3).

**Pattern 1: Familial epilepsies.** Identified epilepsy syndromes in this EEG category include benign familial neonatal seizures, benign familial neonatal infantile seizures, autosomal dominant nocturnal frontal lobe epilepsy, autosomal dominant lateral temporal lobe epilepsy, and autosomal dominant partial epilepsy with auditory features.

**Pattern 2: Genetic generalized epilepsies.** Children with genetic generalized epilepsies often have EEG features that could be appropriately placed with the second category of EEG findings. While specific details about

**Figure 3** Genetics, clinical outcome, and epilepsy syndrome examples of each EEG pattern group

Electroclinical syndromes					
Age					
EEG features	Neonatal	Infancy	Childhood	Adolescence	Variable
1. Normal	• Benign familial neonatal epilepsy	• Benign familial infantile epilepsy	• AD nocturnal frontal lobe epilepsy	• AD epilepsy with auditory features • AD familial temporal lobe epilepsy	• Familial focal epilepsy with variable foci
2. Generalized stereotyped spikes; normal background	• No recognized syndromes as yet	• Myoclonic epilepsy in infancy	• Myoclonic atonic epilepsy • Childhood absence epilepsy • Epilepsy with myoclonic absences • Jeavons syndrome	• Juvenile absence epilepsy • Juvenile myoclonic epilepsy • Epilepsy with GTCs	• No recognized syndromes as yet
3. Focal/multifocal stereotyped spikes; normal background	• No recognized syndromes as yet	• No recognized syndromes as yet	• Panayiotopoulos syndrome • Late onset occipital epilepsy (Gastaut type) • Benign epilepsy with centro-temporal spikes • Self-limited epilepsy with other stereotyped focal spikes	• No recognized syndromes as yet	• No recognized syndromes as yet
4a. Multifocal pleomorphic spikes; background slowing	• No recognized syndromes as yet	• Dravet syndrome • EFMR • Migrating focal seizures	• Myoclonic encephalopathy in nonprogressive disorders	• Progressive myoclonus epilepsies	• Landau-Kleffner syndrome • Continuous spike-wave during sleep
4b. Multifocal pleomorphic spikes; discontinuity, background slowing	• EME (Aicardi) • EIEE (Ohtahara)	• West syndrome • Late infantile epileptic encephalopathy	• Lennox-Gastaut syndrome	• No recognized syndromes as yet	• No recognized syndromes as yet
Nonsyndromic epilepsies					
5a. Focal pleomorphic spikes; focal slowing/attenuation	<ul style="list-style-type: none"> <li>• Epilepsies due to focal structural lesions</li> <li>• Can have homotopic EEG foci</li> <li>• Clinical expression will vary as a function of age</li> </ul>				
5b. Focal pleomorphic spikes; focal slowing/attenuation; discontinuity					

Familial predisposition

AD = autosomal dominant; EFMR = epilepsy and mental retardation restricted to females; EIEE = early infantile epileptic encephalopathy; EME = early myoclonic encephalopathy; GTC = generalized tonic-clonic seizure.

the generalized spike-wave discharges might allow some degree of segregation between the epilepsies in this group, the predominant seizure type may be even more specific in identifying the precise syndrome. For example, if a child demonstrates absence seizures as the predominant seizure type, possible epilepsy syndromes for consideration would include childhood absence epilepsy or juvenile absence epilepsy. These are often easily separated according to the age at onset. If simple myoclonic seizures are the predominant seizure type, then myoclonic epilepsy in infancy or juvenile myoclonic epilepsy are considerations, again, easily distinguished by the age at presentation. There are also epilepsy syndromes with more complex myoclonic seizures, such as myoclonic-absence epilepsy, epilepsy with myoclonic-atonic seizures, or Jeavons syndrome.

**Pattern 3: Self-limited epilepsies with focal spikes.** Panayiotopoulos syndrome, benign epilepsy with centro-temporal spikes, and late onset occipital epilepsy (Gastaut type) may be included under this EEG pattern.

**Pattern 4: Epilepsies with encephalopathy.** *Epileptogenic encephalopathies.* There are few well-recognized syndromes in this category, and this grouping may seem to contain a collection of specific diseases rather than a list of epilepsy syndromes. Few EEG clues exist to allow precise identification of the underlying condition, but important exceptions include ring chromosome,<sup>27</sup> malignant migrating focal seizures of infancy,<sup>28</sup> and Angelman syndrome.<sup>29</sup> Often, it is the details of the clinical presentation that suggest the underlying cause (e.g., Dravet syndrome, epilepsy in females with mental retardation).

*Epileptic encephalopathies.* Examples of syndromes that are associated with this EEG category include the early epileptic encephalopathies (including early myoclonic encephalopathy and early infantile epileptic encephalopathy [EIEE]), West syndrome, late infantile epileptic encephalopathy, and Lennox-Gastaut syndrome.

**Special considerations.** There are situations that may require additional consideration. First, there may be some cases where the EEG findings may be consistent with multiple categories simultaneously, as is



sometimes the case with clinical presentations. EEG and clinical features may sometimes suggest a differential diagnosis but not necessarily a specific syndrome. Examples are generalized spike-wave discharges with concurring stereotyped focal spikes suggesting either absence epilepsy or a self-limited epilepsy (BCSSS).<sup>30,31</sup> Second, in some children, EEGs may evolve and fit different categories at different time points. This is classically seen in the epileptic encephalopathies, where infants may originally present with EIEE and then evolve to West syndrome, or where children with West syndrome evolve to Lennox-Gastaut syndrome. Third, not all EEGs are informative. EEGs are subject to sampling phenomenon and multiple EEGs may be needed before declarative features are found.

**DISCUSSION** **How are these groupings helpful?** One can reliably distinguish 5 groups of EEG findings based upon a consideration of the background and the specific characteristics of the epileptiform discharges. Such a simple categorization of interictal EEG abnormalities in children with epilepsy may be helpful in several ways. First, and from the start, we envisioned this as primarily an educational tool, designed to help the individual learning pediatric EEG how to abstract and apply the information in a clinically useful way. Second, the literature review suggests that these groupings may help to identify the relative role of genetics as structural underpinnings and provide a stepwise logic for the clinical evaluation. One might argue that patients with the first 3 types of epilepsy including familial, genetic generalized, and self-limited epilepsies do not require imaging or urgent referral for other diagnostic testing. Patients with epileptic encephalopathies, on the other hand, require a thorough diagnostic evaluation, including a search for de novo genetic mutations in those with no other ready explanation. Patients in the focal structural group should, of course, have high-quality brain imaging. Third, the clustering of epilepsy syndromes with the groups may help to inform the clinician, in broad terms, about what types of treatment to consider, and equally notable, what to avoid. Fourth, and finally, our pilot data would suggest that this simple categorization may be useful in helping the primary care physician to triage between patients requiring urgent evaluation by specialists and those who could be managed in less advanced settings. Patients with encephalopathic epilepsies and focal structural epilepsies may particularly benefit from early referral to specialists and centers skilled in these types of evaluations. This would require confirmation in a larger prospective study of children with new-onset epilepsies.

## AUTHOR CONTRIBUTIONS

D.R.N. conceptualized the idea. D.R.N. and S.H.K. drafted the manuscript. D.R.N. and C.M.K. revised the manuscript. A.J.K. and S.H.K. conducted the pilot project.

## STUDY FUNDING

No targeted funding reported.

## DISCLOSURE

S. Kim received research support from the Dravet Syndrome Foundation. C. Korff and A. Kim report no disclosures relevant to the manuscript. D. Nordli received funding as a co-investigator in NIH/National Institute of Neurological Disorders and Stroke 1-RO1-NS43209 and is an associate editor for UpToDate. Go to Neurology.org for full disclosures.

Received October 7, 2014. Accepted in final form April 2, 2015.

## REFERENCES

1. Paciorkowski AR, Thio LL, Dobyns WB. Genetic and biologic classification of infantile spasms. *Pediatr Neurol* 2011;45:355–367.
2. Bjerre I, Corelius E. Benign familial neonatal convulsions. *Acta Paediatr Scand* 1968;57:557–561.
3. Vigeveno F, Fusco L, Di Capua M, Ricci S, Sebastianelli R, Lucchini P. Benign infantile familial convulsions. *Eur J Pediatr* 1992;151:608–612.
4. Scheffer I, Berkovic S, Bhatia K, et al. Autosomal dominant frontal epilepsy misdiagnosed as sleep disorder. *Lancet* 1994;343:515–517.
5. Ottman R, Risch N, Hauser WA, et al. Localization of a gene for partial epilepsy to chromosome 10q. *Nat Genet* 1995;10:56–60.
6. Ottman R, Winawer MR, Kalachikov S, et al. *LGII* mutations in autosomal dominant partial epilepsy with auditory features. *Neurology* 2004;62:1120–1126.
7. Oldani A, Zucconi M, Asselta R, et al. Autosomal dominant nocturnal frontal lobe epilepsy: a video-polysomnographic and genetic appraisal of 40 patients and delineation of the epileptic syndrome. *Brain* 1998;121:205–223.
8. Vadlamudi L, Milne RL, Lawrence K, et al. Genetics of epilepsy: the testimony of twins in the molecular era. *Neurology* 2014;83:1042–1048.
9. Peljto AL, Barker-Cummings C, Vasoli VM, et al. Familial risk of epilepsy: a population-based study. *Brain* 2014;137:795–805.
10. Perucca E, Gram L, Avanzini G, Dulac O. Antiepileptic drugs as a cause of worsening seizures. *Epilepsia* 1998;39:5–17.
11. Panayiotopoulos CP. Idiopathic childhood occipital epilepsies. In: Roger J, Bureau M, Dravet CH, Genton P, Tassinari CA, Wolf P, eds. *Epileptic Syndromes in Infancy, Childhood, and Adolescence*. Eastleigh: John Libbey; 2002:203–227.
12. Bali B, Kull LL, Strug LJ, et al. Autosomal dominant inheritance of centrottemporal sharp waves in rolandic epilepsy families. *Epilepsia* 2007;48:2266–2272.
13. Vadlamudi L, Kjeldsen MJ, Corey LA, et al. Analyzing the etiology of benign rolandic epilepsy: a multicenter twin collaboration. *Epilepsia* 2006;47:550–555.
14. Rudolf G, Valenti MP, Hirsch E, Szepetowski P. From rolandic epilepsy to continuous spike-and-waves during sleep and Landau-Kleffner syndromes: insights into possible genetic factors. *Epilepsia* 2009;50:25–28.
15. Vadlamudi L, Harvey AS, Connellan MM, et al. Is benign rolandic epilepsy genetically determined? *Ann Neurol* 2004;56:129–132.

16. Lal D, Reinthaler EM, Altmüller J, et al. *RBFOX1* and *RBFOX3* mutations in rolandic epilepsy. *PLoS One* 2013; 8:e73323.
17. Lesca G, Rudolf G, Bruneau N, et al. *GRIN2A* mutations in acquired epileptic aphasia and related childhood focal epilepsies and encephalopathies with speech and language dysfunction. *Nat Genet* 2013;45:1061–1066.
18. Guerrini R, Pellacani S. Benign childhood focal epilepsies. *Epilepsia* 2012;53:9–18.
19. Allen AS, Berkovic SF, Cossette P, et al. De novo mutations in epileptic encephalopathies. *Nature* 2013;501:217–221.
20. Lemke JR, Riesch E, Scheurenbrand T, et al. Targeted next generation sequencing as a diagnostic tool in epileptic disorders. *Epilepsia* 2012;53:1387–1398.
21. Kodera H, Kato M, Nord AS, et al. Targeted capture and sequencing for detection of mutations causing early onset epileptic encephalopathy. *Epilepsia* 2013;54:1262–1269.
22. Yamatogi Y, Ohtahara S. Age-dependent epileptic encephalopathy: a longitudinal study. *Folia Psychiatr Neurol Jpn* 1981;35:321–332.
23. Lee YJ, Berg AT, Nordli DR. Clinical spectrum of epileptic spasms in children. *Brain Dev* 2015;37:37–48.
24. Caraballo RH, Ruggieri V, Gonzalez G, et al. Infantile spasms without hypsarrhythmia: a study of 16 cases. *Seizure* 2011;20:197–202.
25. Asano E, Juhász C, Shah A, et al. Origin and propagation of epileptic spasms delineated on electrocorticography. *Epilepsia* 2005;46:1086–1097.
26. Berg AT, Berkovic SF, Brodie MJ, et al. Revised terminology and concepts for organization of seizures and epilepsies: report of the ILAE Commission on Classification and Terminology, 2005–2009. *Epilepsia* 2010;51:676–685.
27. Augustijn P, Parra J, Wouters C, Joosten P, Lindhout D, van Emde Boas W. Ring chromosome 20 epilepsy syndrome in children: electroclinical features. *Neurology* 2001;57:1108–1111.
28. Coppola G, Plouin P, Chiron C, Robain O, Dulac O. Migrating partial seizures in infancy: a malignant disorder with developmental arrest. *Epilepsia* 1995;36:1017–1024.
29. Boyd S, Harden A, Patton M. The EEG in early diagnosis of the Angelman (happy puppet) syndrome. *Eur J Pediatr* 1988;147:508–513.
30. Caraballo RH, Cersósimo RO, Fejerman N. Late-onset, “Gastaut type,” childhood occipital epilepsy: an unusual evolution. *Epileptic Disord* 2005;7:341–346.
31. Caraballo RH, Fontana E, Darra F, et al. Childhood absence epilepsy and electroencephalographic focal abnormalities with or without clinical manifestations. *Seizure* 2008;17:617–624.