

PEDIATRICS®

OFFICIAL JOURNAL OF THE AMERICAN ACADEMY OF PEDIATRICS

Management of Dental Trauma in a Primary Care Setting

Martha Ann Keels and THE SECTION ON ORAL HEALTH

Pediatrics 2014;133:e466; originally published online January 27, 2014;

DOI: 10.1542/peds.2013-3792

The online version of this article, along with updated information and services, is located on the World Wide Web at:

<http://pediatrics.aappublications.org/content/133/2/e466.full.html>

PEDIATRICS is the official journal of the American Academy of Pediatrics. A monthly publication, it has been published continuously since 1948. PEDIATRICS is owned, published, and trademarked by the American Academy of Pediatrics, 141 Northwest Point Boulevard, Elk Grove Village, Illinois, 60007. Copyright © 2014 by the American Academy of Pediatrics. All rights reserved. Print ISSN: 0031-4005. Online ISSN: 1098-4275.

American Academy of Pediatrics

DEDICATED TO THE HEALTH OF ALL CHILDREN™





CLINICAL REPORT

Management of Dental Trauma in a Primary Care Setting

abstract

FREE

The American Academy of Pediatrics and its Section on Oral Health have developed this clinical report for pediatricians and primary care physicians regarding the diagnosis, evaluation, and management of dental trauma in children aged 1 to 21 years. This report was developed through a comprehensive search and analysis of the medical and dental literature and expert consensus. Guidelines published and updated by the International Association of Dental Traumatology (www.dental-traumaguide.com) are an excellent resource for both dental and non-dental health care providers. *Pediatrics* 2014;133:e466–e476

INTRODUCTION

By 14 years of age, 30% of children have experienced a dental injury.¹ Many of these children are taken directly to their medical home, an urgent care center, or an emergency department for evaluation and treatment. Few of these facilities employ a dentist; therefore, the primary care provider for the injured child will most likely be a pediatrician or other physician. In many instances, the injured tooth's survival is time-dependent. Therefore, it is imperative for the pediatrician to manage the acute dental injury properly to afford the child's dentition the best possible outcome. Pediatricians can also advocate for dental injury–preventive measures, as they provide other injury-prevention messages for caregivers of children and preparticipation sports physicals.

DENTAL TRAUMA PREVENTION

Pediatricians can advocate for dental injury–preventive measures as they provide other injury-prevention messages during well-child visits. Caregivers should be counseled about participation in sports and activities that are appropriate for the child's age and development, general household safety measures such as stairway gates and removal of trip hazards, and adult supervision of activities that could lead to dental trauma. Although these measures will not prevent all dental injuries, they can reduce their incidence and severity.

As part of a preparticipation sports physical, physicians should recommend sports mouth guards to prevent sports-related mouth injuries. Currently, the US National Collegiate Athletic Association requires mouth guards for 4 sports (ice hockey, lacrosse, field hockey,

Martha Ann Keels, DDS, PhD, and THE SECTION ON ORAL HEALTH

KEY WORDS

dental trauma, dental injury, tooth, teeth, dentist, pediatrician

ABBREVIATION

CT—computed tomography

This document is copyrighted and is property of the American Academy of Pediatrics and its Board of Directors. All authors have filed conflict of interest statements with the American Academy of Pediatrics. Any conflicts have been resolved through a process approved by the Board of Directors. The American Academy of Pediatrics has neither solicited nor accepted any commercial involvement in the development of the content of this publication.

The guidance in this report does not indicate an exclusive course of treatment or serve as a standard of medical care. Variations, taking into account individual circumstances, may be appropriate.

www.pediatrics.org/cgi/doi/10.1542/peds.2013-3792

doi:10.1542/peds.2013-3792

All clinical reports from the American Academy of Pediatrics automatically expire 5 years after publication unless reaffirmed, revised, or retired at or before that time.

PEDIATRICS (ISSN Numbers: Print, 0031-4005; Online, 1098-4275).

Copyright © 2014 by the American Academy of Pediatrics

and football).² The American Dental Association recommends the use of mouth guards in 29 sports/exercise activities. Sports mouth guards can be made of a variety of materials: polyvinyl acetate-polyethylene or ethylene vinyl acetate copolymer, polyvinyl chloride, latex rubber, or polyurethane. Mouth guards can be custom made in the dental office from an impression of the patient's maxillary arch and can also be purchased, typically in a store that carries sports-related items. Purchased mouth guards can be customized by boiling the mouth guard to soften the material and then biting into the mouth guard to create an impression of the upper teeth, which helps create a better fit. Stock mouth guards can also be purchased, but they are not as well adapted to the teeth. Impact studies have shown that wearing any type of mouth guard reduces the risk of tooth injury compared with not wearing a mouth guard.

DENTAL TRAUMA ASSESSMENT

For all dental injuries, it is important to follow a systematic approach.³ Before initiating treatment, an abbreviated medical and dental history should be obtained to gain information vital to urgent care. Questions with respect to **how, when, and where** the dental injury occurred are important for determining the need for a **tetanus booster**, the possibility of **child abuse**, and the possibility of a **head injury**.⁴ Physicians have the legal obligation to explore and report reasonable suspicions of child abuse. Given the proximity of the dentition to the cranium, it is important to complete an **age-appropriate neurologic assessment**, which may include inquiring whether the child experienced loss of consciousness, dizziness, headache, or nausea and vomiting. If a concussion or a more severe intracranial injury is suspected, then protection of the cervical spine and

immediate medical evaluation should be prioritized.⁵ Specific to the teeth, disturbances in the **occlusion (bite) should be assessed** because this may reveal a displaced tooth or an alveolar or jaw fracture. Lastly, inquiring about **tooth sensitivity or pain to hot and/or cold exposures** may indicate that the dentin and/or pulp tissue are exposed, requiring immediate referral to a dentist.

The clinical examination should include thorough evaluation of the face, lips, and oral musculature for soft tissue lesions. To facilitate an accurate extraoral and intraoral examination, the face and oral cavity should be cleansed with water or saline. The **facial skeleton should be palpated for signs of fractures**. The dental trauma region should be inspected for fractures, abnormal **tooth position, and tooth mobility**. Identifying whether the injured tooth is a primary versus a permanent tooth is important in the management of certain types of dental injuries. In general, children younger than 5 years are in the primary dentition (Fig 1).^{*} The 20 primary teeth are named alphabetically starting with tooth A in the upper right posterior quadrant. **From ages 6 through 12 years, children are in the mixed dentition** in which they are exchanging the primary teeth for the permanent teeth. After 8 or 9 years of age, most of the incisors are permanent teeth, with a mixture of primary canines and molars until the age of 12 years. **By 13 years of age, most children have exfoliated all of their primary teeth and have 28 permanent**

teeth. The permanent teeth follow a numbering system (Fig 2). Discussion with the parent/caregiver as to whether the child has lost any primary teeth from natural exfoliation can help identify whether the child is in full primary dentition or mixed dentition. Primary incisor teeth are considerably smaller in size than permanent teeth. Physicians can use their own dentition as a point of reference to estimate the size of permanent teeth for comparative purposes. In addition to proper tooth identification, the direction of any tooth displacement as well as any pulp involvement should be noted. Familiarity with tooth anatomy will assist in determining the extent of injury present (Fig 3).

After the initial clinical assessment and administration of first aid, the injured region should be examined with the most appropriate radiographic techniques. Radiographic assessment of an injured tooth is best accomplished with conventional intraoral dental radiographs instead of computed tomography (CT). There is considerably less radiation involved with conventional intraoral dental radiographs than with a head CT scan. Several clinical studies have demonstrated that multiple dental radiographs from different angulations are needed to detect displacement of the tooth in its socket as well as presence of root fractures.^{6,7} If a lip laceration is present, an intraoral soft tissue radiograph may be indicated to visualize any foreign bodies, including tooth fragments. These types of radiographs are more feasibly obtained by a dentist because a general emergency department or radiologist's facility may not be equipped to perform radiography, and a dentist's evaluation may be required to order the correct radiographic studies. **If a maxillary or mandibular fracture is suspected, a panoramic film, cone-beam CT, or CT scan may be indicated.** For all

*All black and white drawings are reproduced with permission from Fisher M, Keels MA, McGraw T, Neal C, Pinkerton K. Dental trauma. In: Marcus JR, Erdmann D, Rodriguez ED, eds. *Essentials of Craniomaxillofacial Trauma*. St Louis, MO: Quality Medical Publishing; 2012:313–321. All color drawings and clinical photographs and radiographs are reproduced from www.dentaltraumaguide.com with written permission from Dr Jens Ove Andreasen.

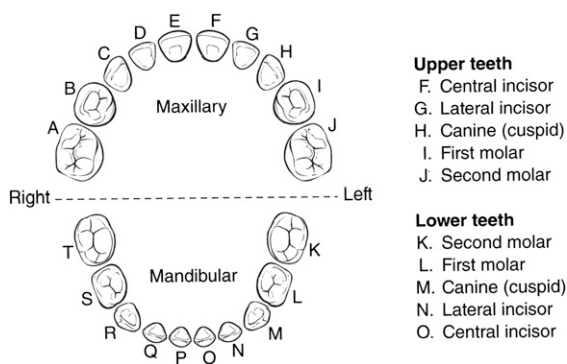


FIGURE 1
Primary dentition.

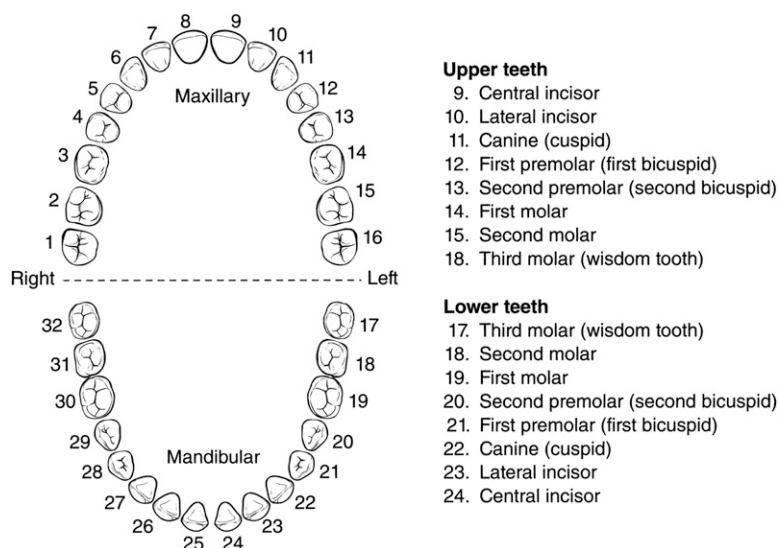


FIGURE 2
Permanent dentition.

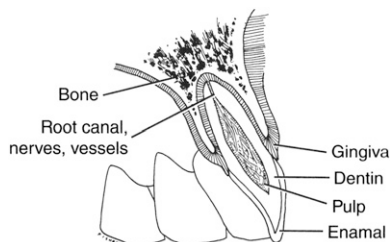


FIGURE 3
Tooth diagram.

radiograph selections with dental trauma, the safety principle of ALARA (as low as reasonably achievable) should be followed to minimize exposure to radiation.⁸

If possible, and with appropriate informed consent, digital photographic documentation of the trauma is helpful because it offers an exact documentation of the extent of injury and can be sent electronically to a consulting dentist for guidance in managing the acute phase of treatment. Photographs can also be used later to facilitate any legal or insurance claims related to the injury.

With the combined information from the clinical and radiographic examinations, a diagnosis can be made, and treatment can be planned. The man-

agement of dental trauma is described here in 2 parts: trauma involving the primary dentition and trauma involving the permanent dentition. Depending on the type of dental injury, there can be distinct differences in how a primary tooth is managed compared with a permanent tooth.

DENTAL TRAUMA CLASSIFICATIONS

Concussion

A concussed tooth is **tender** to touch, but there is **no increased mobility or displacement**. There is **no sulcular bleeding** (at the margin of the tooth and gums).

Subluxation

A subluxated tooth presents with **abnormal mobility** but **no displacement**. Sulcular **bleeding** is present (Fig 4).

Lateral Luxation

Clinically, a luxated tooth is **displaced** laterally, most often in a **palatal/lingual direction** (Fig 5). The injured tooth **may be mobile** or firmly locked into the displaced position.

Extrusive Luxation

Partial **vertical displacement** of the injured tooth from its socket is classified as an extrusive luxation injury or a partial avulsion (Fig 6).

Intrusive Luxation

In this type of luxation, the tooth is **forced into the alveolus** and **usually locked without any mobility** (Fig 7). The tooth **appears shortened**. In cases of severe intrusion, the tooth may appear to be missing. **Bleeding** from the gingival sulcus is present.

Avulsion

An avulsion is the **complete displacement of the tooth out of the socket** (Fig 8). The periodontal ligament is severed, and the **alveolus may be fractured**.

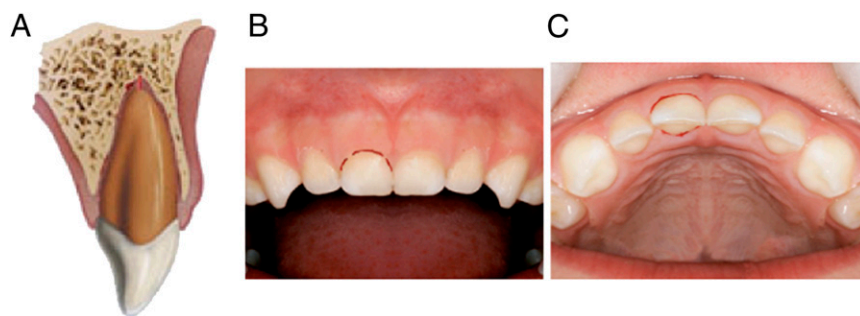


FIGURE 4
Subluxation.

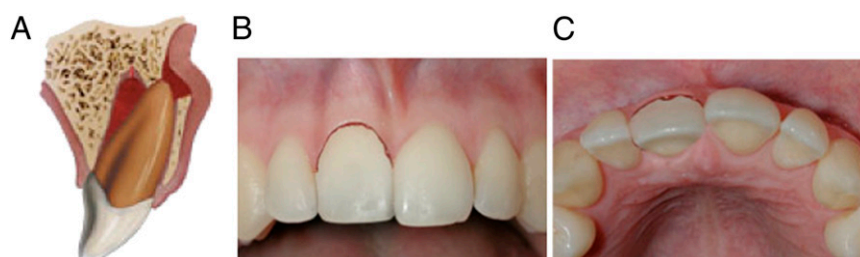

FIGURE 5
Lateral luxation.

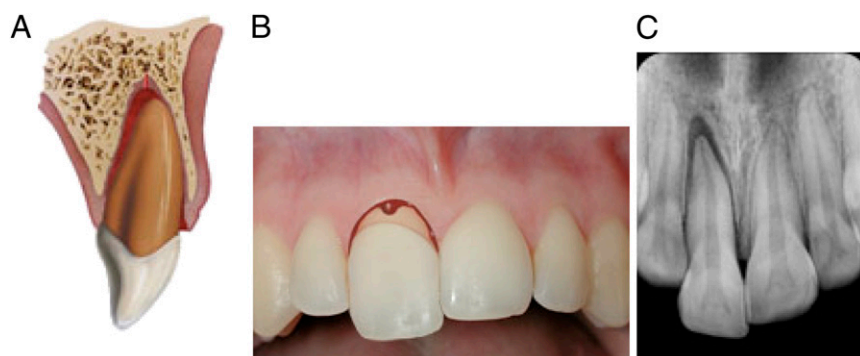

FIGURE 6
Extrusive luxation.

Infraction (Crack)

An infraction is a crack or craze line in the surface of the enamel. The tooth appears intact, but crack lines may be visualized by shining a focused source of light, such as the otoscope, onto the crown of the tooth in an axial direction.

Enamel Only (Uncomplicated) Crown Fracture

If the fracture of the tooth is contained within the enamel layer only, it is considered to be an uncomplicated fracture. There is generally limited sensitivity associated with this type of injury unless there is a rough edge

that is causing irritation to the tongue or lips.

Enamel and Dentin (Uncomplicated) Crown Fracture

If the fracture of the tooth is contained within the enamel and dentin layers without exposure of the pulpal tissues, then the injury is classified as an uncomplicated fracture of enamel and dentin. When the dentin is exposed, there is frequently sensitivity associated with exposure to air, food, or beverages (Fig 9).

Crown Fracture With Exposed Pulp (Complicated)

If the fracture of the tooth exposes the pulpal tissue, the injury is classified as a complicated fracture. Crown fractures with exposed pulp are frequently sensitive and introduce an increased risk of infection because the pulp tissue is exposed to the oral flora (Fig 10). In severe fractures, the root may be involved, creating a crown-root fracture (Fig 11).

Root Fracture

When the crown segment of an injured primary incisor displays mobility, there is a risk of a root fracture. This can only be verified with an intraoral dental radiograph (Fig 12).

Alveolar Fracture

Dislocation of several teeth that move together when palpated suggests that there is a fracture of the alveolus (Fig 13).

PRIMARY DENTAL TRAUMA EPIDEMIOLOGY AND MANAGEMENT

Epidemiology

In children 0 to 6 years of age, oral injuries are ranked as the second most common injury, accounting for

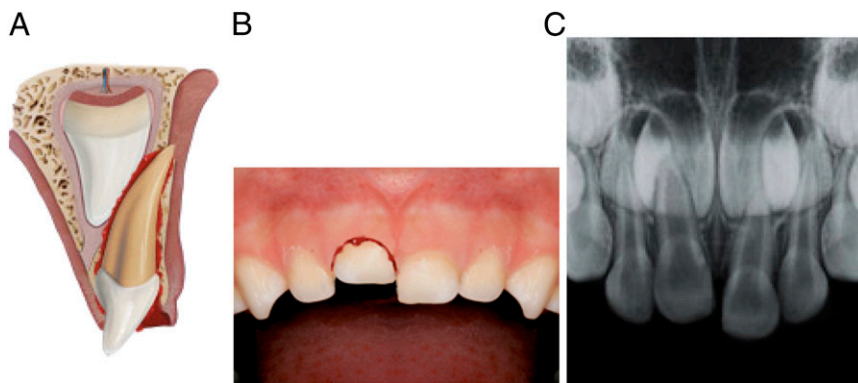


FIGURE 7
Intrusive luxation.

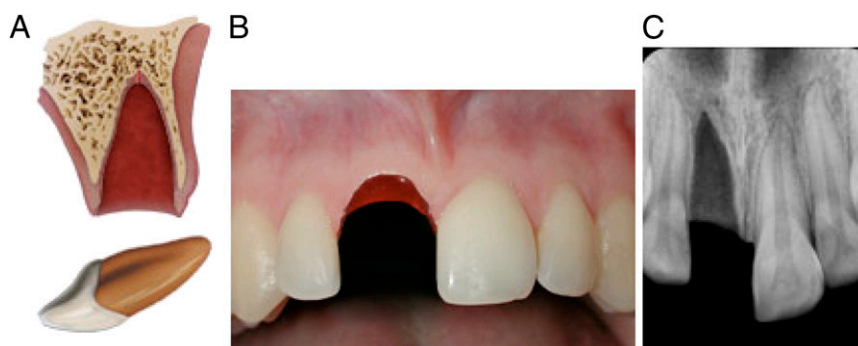

FIGURE 8
Avulsion.

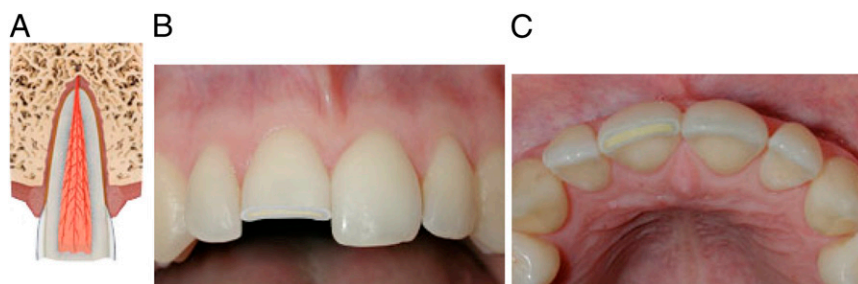

FIGURE 9
Uncomplicated crown fracture (no pulp exposure).

almost 20% of all bodily injuries.⁹ The greatest incidence of trauma to the primary teeth occurs at 2 to 3 years of age, when motor coordination is developing.^{10,11} The most common teeth injured in the primary dentition are the maxillary incisors. These teeth are typically present in the mouth from 12 months to 6 years of

age. Exfoliation of the maxillary incisors may vary from 5 to 7 years of age. The most common dental injury to the primary dentition is a luxation.¹⁰ Dental injuries in the primary dentition occur more often in boys. Child abuse should be considered as a possible etiology in any child younger than 5 years with trauma

affecting the lips, gingiva, tongue, palate, and severe tooth injury.^{12,13}

Concussion

No immediate treatment is indicated for a dental concussion. Observing the injured tooth for possible future pulpal necrosis is recommended. Pulpal necrosis in a primary tooth may cause the tooth to appear gray in color or to have a parulis (gingival abscess or gum boil) on the gingiva adjacent to the root of the affected tooth. If tooth discoloration or a localized parulis forms, then referral to a dentist within a few days is recommended.

Subluxation

No immediate treatment is indicated for a subluxated primary tooth. The injured primary tooth should be followed for possible future pulpal necrosis (as described previously). If tooth discoloration develops or a localized parulis appears, then referral to a dentist within a few days is recommended. If more extensive gingival or facial swelling develops, then immediate referral to a dentist is recommended.

Lateral Luxation

If the tooth displacement is minor, then gentle repositioning is indicated, or acceptance of the position as spontaneous repositioning will take place. For more severe displacement injuries, the child's ability to bite teeth together may be affected. It is important to ensure that the tooth position does not interfere with the occlusion (bite). Asking the child to say "cheese" or the letter "e" allows one to visualize the occlusion and determine whether the luxated tooth is interfering with the complete closure of the bite. If the child is unable to bite the teeth

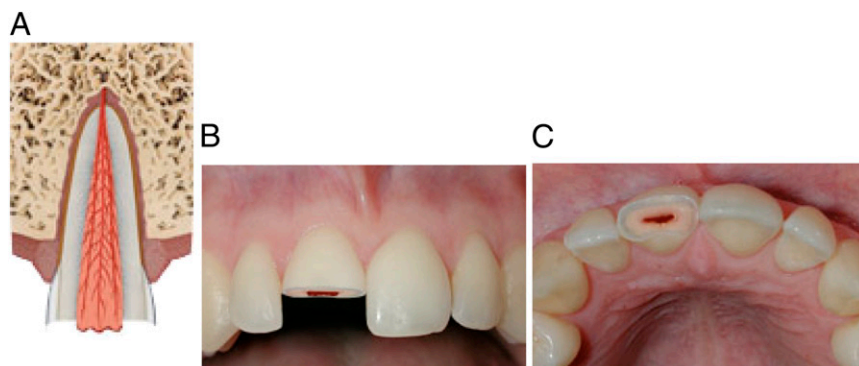


FIGURE 10
Complicated crown fracture (pulp exposure).

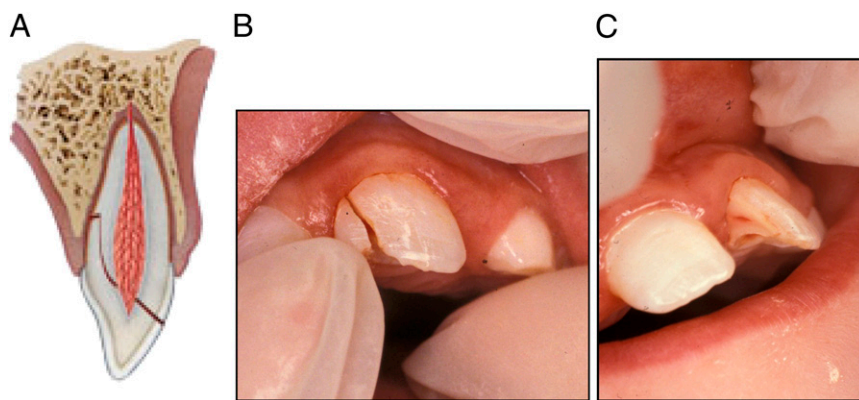


FIGURE 11
Crown root fracture.

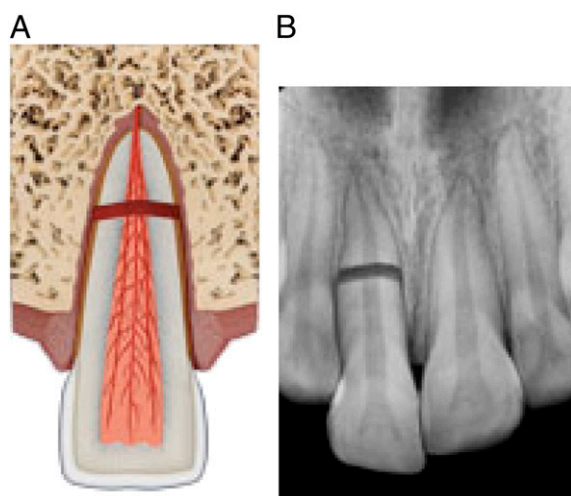


FIGURE 12
Root fracture.

interdigitate and masticate food properly. If the luxated tooth is near exfoliation and interfering with the bite, then extraction of the injured tooth is indicated. Immediate referral to a dentist is recommended.

Extrusive Luxation

If the extrusion is minor, then gentle repositioning is indicated. In severe extrusive injuries (>3 mm), extraction is indicated. Immediate referral to a dentist is recommended.

Intrusive Luxation

When a primary tooth is intruded, it will typically reerupt without intervention. In cases of severe intrusion, an intraoral radiograph is indicated to determine the location or absence of the injured tooth. In rare circumstances, the tooth may become ankylosed (fused to bone) and require extraction to prevent blocking of the eruption of the permanent successor. Observation is indicated for all intruded primary incisors. Immediate referral to a dentist is indicated for more severe intrusions or to rule out avulsion of the tooth. With any intruded primary tooth, there is a potential for damage to the developing permanent tooth germ.

Avulsion

When a primary tooth is avulsed and the tooth was found, there is no treatment indicated. An avulsed primary tooth should not be replanted to avoid damage to the underlying permanent tooth germ.⁸ If the tooth is not found, clinical and radiographic examination can confirm that the tooth is not intruded. A chest radiograph may be indicated if the child displays breathing difficulties to ensure the tooth was not aspirated. The subsequent avulsion site will need to be monitored for healing and potential space loss. If the child has an active digit-sucking habit and avulses

together, then the tooth will need to be repositioned by the urgent care provider, or the child should be im-

mediately referred to a dentist. It is important to ensure that the posterior teeth (molars) are able to fully

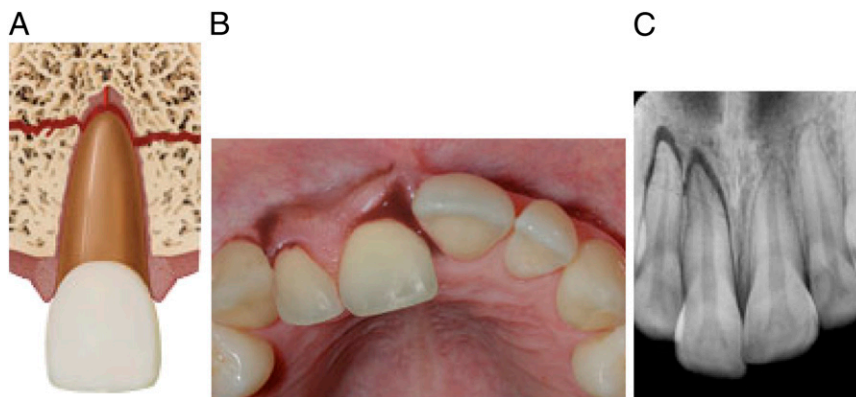

FIGURE 13
Alveolar fracture.

a maxillary incisor, the potential for space loss in the upper anterior region exists. An appliance with an artificial tooth may be indicated to prevent space loss.¹⁴ Therefore, referral to a dentist within a few days is recommended to provide space management.

Infraction (Crack)

If the primary tooth sustains a marked crack in the enamel without loss of tooth structure, then placing a resin sealant over the infraction line may be indicated to avoid obvious staining of the line. In many cases, no treatment is indicated; however, the tooth should be monitored for signs of pulpal necrosis until exfoliation.

Enamel Only (Uncomplicated) Crown Fracture

If the fracture of the primary tooth is contained within the enamel surface only, then the tooth fracture area can be smoothed with a dental handpiece and polishing bur or left untreated if the fracture site is smooth to touch. This is best accomplished by a dentist and does not require immediate attention unless there is a sharp edge causing soft tissue injury. The tooth should be monitored by a dentist for signs of pulpal necrosis until exfoliation.

Enamel and Dentin (Uncomplicated) Crown Fracture

A primary tooth with an uncomplicated fracture involving enamel and dentin can be restored with tooth-colored dental material. A referral to a dentist within a few days is indicated; if the child's behavior precludes dental restorative care, then the tooth fracture area can be smoothed with a dental handpiece and polishing bur or left untreated if the fracture site is smooth to touch. The tooth should be monitored by a dentist for signs of pulpal necrosis until exfoliation.

Crown Fracture With Exposed Pulp (Complicated)

If the fracture of the primary tooth exposes the pulpal tissue, then a pulpotomy or pulpectomy and restorative care is indicated. If the child's behavior precludes pulp therapy and dental restorative care, then extraction of the traumatized primary tooth is indicated. If the tooth is treated, then it will need to be monitored for signs of pulpal necrosis until exfoliation. With severe crown fractures, the root may also be involved. If a crown root fracture is suspected, an intraoral periapical radiograph should be obtained to determine the extent of injury to the tooth and root. Extraction of the tooth is indicated if the fracture extends onto the root surface. Immediate referral to

a dentist is indicated for a tooth with a complicated fracture. If the tooth is removed, then a space maintainer may be indicated if the child has an active digit-sucking habit.

Root Fracture

If a root fracture of a primary tooth is suspected because of excessive tooth mobility, then referral to a dentist for a radiographic examination is indicated. The timing of the referral to the dentist is dependent on the amount of crown mobility. If there is concern for aspiration of the crown portion, then immediate referral to a dentist is indicated; subsequent management of the injured tooth is dependent on the location of the root fracture. The closer the root fracture is to the apex of the root, the better the prognosis. This type of root fracture rarely requires treatment. Conversely, the closer the root fracture is to the crown of the tooth, the poorer the prognosis. The crown segment is usually removed, and if the primary root can be removed without damaging the underlying permanent tooth bud, then it can also be extracted. If removal of the root poses a risk to the developing permanent tooth bud, then the residual root can be left and monitored for natural resorption.

Alveolar Fracture

If the trauma involves a fracture of the alveolar bone displayed by dislocation of several teeth that move together, then reposition of the segment and stabilization with a splint is indicated. Immediate referral to a dentist or an oral surgeon is recommended.

Sequelae From Dental Trauma in the Primary Dentition

To optimize the best healing results from trauma sustained by the primary dentition, parents and caregivers should be advised about the

importance of good oral hygiene practices and injury prevention. For the first 10 days after an injury to a primary tooth, the child should eat a soft diet, and sucking on a pacifier or digit should be restricted, if possible.⁹ The routine use of systemic antibiotics in the postoperative care of primary tooth trauma is not indicated.⁹ However, the child's medical condition may require antibiotic coverage. Parents/caregivers should be advised about the potential for crown discoloration, pulp canal obliteration, or pulp necrosis. Children may not report painful symptoms from a necrotic tooth; therefore, parents/caregivers should be vigilant regarding the development of the symptoms of pulp necrosis: gingival swelling, increased mobility, and/or parulis. If any of these symptoms develop, the parent/caregiver should obtain follow-up care with the child's dentist to determine the need for extraction of the previously injured tooth.

PERMANENT DENTAL TRAUMA EPIDEMIOLOGY AND MANAGEMENT

Epidemiology

A 12-year review of the scientific literature reports that 25% of all school-age children experience some form of dental trauma.¹⁵ The most common injury reported in the permanent dentition is an uncomplicated crown fracture involving the maxillary incisors. Injuries to permanent teeth are most often caused by falls, followed by automobile crashes, violence, and sports.¹⁶ Sports-related accidents account for 10% to 39% of all dental injuries in children.¹⁷ During sporting activities, falls, collisions, contact with hard surfaces, and contact with sports-related equipment place the child at risk for oral facial injury. Boys sustain more dental injuries to their permanent teeth than girls. During the adolescent years, the possibility of abuse exists and should be

considered in assessing the cause of dental trauma.

Concussion

No treatment is indicated for a concussed permanent tooth. Observing the injured tooth for possible future pulp necrosis is recommended.

Subluxation

No treatment is indicated for a subluxated permanent tooth. The injured permanent tooth should be followed for possible future pulp necrosis.

Lateral Luxation

For any amount of displacement, it is important to reposition the tooth to its original position. If the displacement is minor, then gentle digital apical pressure to reposition the tooth is indicated. For more significant displacement, dental forceps may need to be used to reposition the tooth in the proper socket position requiring immediate referral to a dentist. It is important to ensure that the tooth position does not interfere with the occlusion (bite). Asking the child to say "cheese" or the letter "e" allows one to visualize the occlusion and to ensure that the posterior teeth (molars) are able to fully interdigitate and masticate food properly. The permanent tooth will need to be stabilized with a flexible splint for 4 weeks. The tooth should be followed for possible periodontal and pulp pathology. After severe permanent tooth luxation, it is possible that the tooth will require root canal treatment.

Extrusive Luxation

If the extrusion is minor, gentle digital pressure to reposition the tooth into the socket is indicated. Immediate referral to a dentist for placement of a flexible splint if the tooth remains mobile after repositioning is recommended. If the extrusion is excessive,

then repositioning with dental forceps may be indicated, requiring immediate referral to a dentist. After repositioning, the tooth should be stabilized with a flexible splint for 2 weeks. The dentist will determine the need for pulp therapy depending on the maturity of the root.

Intrusive Luxation

In cases of mild intrusion, the tooth will typically reerupt gradually on its own. Bleeding from the gingival sulcus is present. If no reeruption is visible after a few weeks, orthodontic or surgical repositioning of the intruded tooth is necessary. Early involvement of a dentist is important to supervise the repositioning of the intruded incisor. In severe intrusion cases, the tooth may not be visible clinically, requiring intraoral radiography to be performed to assess the position of the tooth within the alveolus. In rare circumstances, the intruded tooth may become ankylosed (fused to bone) and require extraction to prevent warping of the alveolar ridge, followed by placement of an artificial tooth.

Avulsion

Avulsion of a permanent tooth is the most serious of all dental injuries.¹⁸ The prognosis of the permanent tooth depends on measures taken immediately after the accident. The treatment of choice is immediate replantation. After the tooth is located, it should be handled by the crown portion only and not the root because the root is covered in fragile fibroblasts important for reattachment to the alveolus. Before replantation, it should be confirmed that the avulsed tooth is a permanent tooth; primary teeth should not be replanted. If the permanent tooth is dirty, it should be washed briefly (10 seconds) under cold running water and repositioned

in the socket. The patient/parent should be encouraged to replant the tooth at the site of the injury. The child should be instructed to bite on a cloth to hold it in position until he or she can get to the doctor's office or emergency department. If this is not possible, the tooth should be placed in a suitable storage medium (eg, a glass of cold milk or balanced salt solution, if available). If no storage media are accessible, then the patient can drool saliva in to a container and use that as a transport medium. Storing an avulsed tooth in water should be avoided because water causes osmotic lysis of the root fibroblasts. After the tooth has been replanted or placed in a proper storage medium, dental care should be obtained immediately. A flexible splint will need to be placed by the dentist for up to 2 weeks. Most teeth will require root canal therapy, which will need to be instituted within 7 to 10 days after replantation. The tooth should be monitored for the potential of bodily rejection in the form of root resorption. Systemic antibiotics are indicated after reimplantation of an avulsed permanent tooth. For children older than 12 years, doxycycline is the recommended antibiotic, and for children younger than 12 years, penicillin is indicated. For children who are allergic to penicillin, clindamycin is recommended.

Infraction (Crack)

If the permanent tooth sustains a marked crack in the enamel without loss of tooth structure, then placing a resin sealant over the infraction line may be indicated to avoid obvious staining of the line.

Enamel Only (Uncomplicated) Crown Fracture

If the fracture of the permanent tooth is contained within the enamel layer only, then the tooth fracture area can be smoothed with a dental handpiece

and polishing bur or left untreated if the fracture site is smooth to touch. There is generally little or no sensitivity associated with fractures involving enamel, so immediate referral to a dentist is not necessary. The tooth should be monitored for signs of pulpal necrosis.

Enamel and Dentin (Uncomplicated) Crown Fracture

If the fracture of the permanent tooth is contained within the enamel and dentin surfaces without exposure of the pulpal tissues, then the tooth can be restored with tooth-colored dental material, or if the tooth fragment is available, it can be rebonded to the tooth. When dentin is exposed, there may be tooth sensitivity, and the patient should be referred to a dentist within a few days. The more sensitive the tooth is, the more expediently the patient should be seen by a dentist to cover the exposed dentin and reduce the discomfort. By covering the exposed dentin, the risk of pulpal bacterial contamination is reduced. The tooth should be monitored for signs of pulpal necrosis.

Crown Fracture With Exposed Pulp (Complicated)

If the fracture of the permanent tooth exposes the pulpal tissue, then appropriate pulp therapy should be rendered by a dentist immediately to preserve pulp vitality (Fig 10).¹⁵ The timeliness of pulp therapy is important in the young permanent tooth. The permanent tooth is considered immature until 3 years after eruption. If the tooth is immature, then it will need to be monitored for signs of continued root development and the lack of pulpal necrosis. If the tooth has a mature root, then root canal therapy is usually the treatment of choice. In severe cases, the fracture line can involve the root—hence, it is known as a crown-root fracture. The crown fragment must be removed, and

the health of the remaining fragment must be determined. In some cases, the remaining fragment can be orthodontically extruded and subsequently restored with a full-coverage crown, or the remaining root can be submerged to maintain the alveolar bone for a future implant. For esthetics and space maintenance, the missing crown can be replaced by an orthodontic retainer with a prosthetic tooth or by creating a temporary bridge using the original crown fragment.

Root Fracture

When the crown segment of an injured permanent incisor displays mobility, referral to a dentist for a radiographic examination is indicated to rule out a root fracture. The subsequent management of the injured tooth is dependent on the location of the root fracture. The closer the root fracture is to the apex of the root, the better the prognosis. This type of root fracture rarely requires treatment. Conversely, the closer the root fracture is to the crown of the tooth, the poorer the prognosis. Splinting is recommended for 4 weeks. If crown segment remains mobile after splinting, then the crown segment is removed, and the residual root can be orthodontically extruded, treated with root canal therapy, and restored.

Alveolar Fracture

If the trauma involves a fracture of the alveolar bone displayed by dislocation of several teeth that move together, then reposition of the segment and stabilization with a splint is indicated. Immediate referral to a dentist or an oral surgeon for repositioning and placement of a stabilization wire is indicated.

Sequelae From Dental Trauma in the Permanent Dentition

To optimize the best healing results from trauma sustained by the permanent dentition, parents and caregivers should

be advised on the importance of good oral hygiene practices and injury prevention. For the first 10 days after an injury to a permanent tooth, the child should eat a soft diet, and digit sucking should be restricted, if possible.^{15,18} The routine use of systemic antibiotics in the postoperative care of dental trauma is not indicated (except in cases of permanent tooth avulsion and reimplantation).⁹ The child's medical history may require antibiotic coverage. Parents/caregivers should be advised about the potential for crown discoloration, root resorption, ankylosis, or pulpal necrosis. Parents/caregivers and the child should be vigilant regarding the development of the symptoms of pulpal and periodontal abnormalities subsequent to the dental injury: crown discoloration, gingival swelling, increased mobility, and/or sinus tract (parulis). If any of these symptoms develop, the parent/caregiver should obtain follow-up care with the child's dentist to determine the need for additional treatment of the previously injured tooth.

CONCLUSIONS

This clinical report provides evidence-based recommendations for the management of dental trauma in children 1 to 21 years of age. When dental trauma cannot be avoided through the use of preventive measures, it emphasizes the importance of proper diagnosis, treatment planning, and follow-up care conducive to a favorable outcome for an injured tooth in a pediatric patient. The report provides decision-making strategies to assist pediatricians and other primary care physicians in diagnosing and managing children who experience dental trauma. Table 1 provides a concise summary of this information. Close collaboration between the medical and dental home are also important

TABLE 1 Dental Treatment Plan for Traumatic Injuries in the Primary and Permanent Dentition

Description	Primary Dentition	Permanent Dentition
Concussion/subluxation	Observe , soft foods for 1 wk, dental radiograph to rule out root fracture	Observe , soft foods for 1 wk, dental radiograph to rule out root fracture
Luxation	Reposition tooth or extract, do not splint	Dental radiograph, reposition tooth, splint for 4 wk
Extrusion	Reposition tooth or extract, do not splint	Dental radiograph, reposition tooth, splint for 2 wk
Intrusion	Dental radiograph, observe and allow to reerupt, extract if alveolar plate is compromised	Dental radiograph, observe and allow to reerupt, surgical or orthodontic repositioning, root canal treatment
Uncomplicated crown fracture	Restore tooth, smooth sharp edges, dental radiograph to rule out root fracture	Restore tooth, smooth sharp edges, radiograph to rule out root fracture
Complicated crown fracture	Dental radiograph, pulp treatment, restore or extract tooth, observe for infection	Dental radiograph, pulp treatment, restore tooth, observe for infection, may require root canal treatment
Root fracture	Dental radiograph, extract if root fracture is in middle or cervical third of root	Dental radiograph, splint, may require root canal treatment; if in cervical third, may need to extract
Avulsion	Do not replant, dental radiograph to rule out intrusion if tooth is not located	Do not handle the root, replant within 30 min or place in recommended transport medium (balanced salt solution, cold milk); dental radiograph, replant and splint as soon as possible; systemic antibiotics, soft diet, chlorhexidine, close follow-up

to facilitate the time-sensitive therapies for dental injuries.

Suggestions for Pediatricians

1. Counsel parents/caregivers about ways to reduce the risk of dental trauma through injury-prevention strategies.
2. Establish collaborative relationships with local general and pediatric dentists to facilitate referral of patients with traumatic dental injuries.
3. Understand the differences between treatment recommendations for primary and permanent tooth traumatic injuries.
4. Recognize when traumatic dental injuries require immediate treatment by a dentist.
5. Recognize when traumatic dental injuries can be initially managed by the pediatrician or primary care

physician with subsequent referral to a dentist.

This document is copyrighted and is property of the American Academy of Pediatrics and its Board of Directors. All authors have filed conflict of interest statements with the American Academy of Pediatrics. Any conflicts have been resolved through a process approved by the Board of Directors. The American Academy of Pediatrics has neither solicited nor accepted any commercial involvement in the development of the content of this publication.

The guidance in this report does not indicate an exclusive course of treatment or serve as a standard of medical care. Variations, taking into account individual circumstances, may be appropriate.

All clinical reports from the American Academy of Pediatrics automatically expire 5 years after publication unless reaffirmed, revised, or retired at or before that time.

LEAD AUTHOR

Martha Ann Keels, DDS, PhD, Immediate Past Chairperson

SECTION ON ORAL HEALTH EXECUTIVE COMMITTEE, 2012–2013

Adriana Segura, DDS, MS, Chairperson
Suzanne Boulter, MD, FAAP

Melinda Clark, MD, FAAP
Rani Gereige, MD, FAAP
David Krol, MD, MPH, FAAP
Wendy Mouradian, MD, FAAP
Rocio Quinonez, DMD, MPH
Francisco Ramos-Gomez, DDS
Rebecca Slayton, DDS, PhD

LIAISONS

Joseph Castellano, DDS – *American Academy of Pediatric Dentistry*
Sheila Strock, DMD, MPH – *American Dental Association*

STAFF

Lauren Barone, MPH

REFERENCES

1. Andreasen JO, Andreasen FM, Andersson L. *Textbook and Color Atlas of Traumatic Injuries to the Teeth*. 4th ed. Copenhagen, Denmark: Munksgaard; 2007:224–225
2. Knapik JJ, Marshall SW, Lee RB, et al. Mouthguards in sport activities: history, physical properties and injury prevention effectiveness. *Sports Med*. 2007;37(2):117–144
3. Bakland LK, Andreasen JO. Examination of the dentally traumatized patient. *J Calif Dent Assoc*. 1996;24(2):35–37, 40–44
4. American Academy of Pediatric Dentistry. Assessment of acute traumatic dental injuries. *Pediatr Dent*. 2012/2013;34(6):341–342
5. Halstead ME, Walter KD; Council on Sports Medicine and Fitness. American Academy of Pediatrics. Clinical report—sport-related concussion in children and adolescents. *Pediatrics*. 2010;126(3):597–615
6. Andreasen FM, Andreasen JO. Diagnosis of luxation injuries: the importance of standardized clinical, radiographic and photographic techniques in clinical investigations. *Endod Dent Traumatol*. 1985;1(5):160–169
7. Andreasen FM, Andreasen JO. Resorption and mineralization processes following root fracture of permanent incisors. *Endod Dent Traumatol*. 1988;4(5):202–214
8. US Nuclear Regulatory Commission. 10 CFR, §20.1003 (2013)
9. Malmgren B, Andreasen JO, Flores MT, et al; International Association of Dental Traumatology. International Association of Dental Traumatology guidelines for the management of traumatic dental injuries: 3. Injuries in the primary dentition. *Dent Traumatol*. 2012;28(3):174–182
10. Flores MT. Traumatic injuries in the primary dentition [review]. *Dent Traumatol*. 2002;18(6):287–298
11. Avşar A, Topaloglu B. Traumatic tooth injuries to primary teeth of children aged 0–3 years. *Dent Traumatol*. 2009;25(3):323–327
12. Kellogg N; American Academy of Pediatrics Committee on Child Abuse and Neglect. Oral and dental aspects of child abuse and neglect. *Pediatrics*. 2005;116(6):1565–1568
13. da Fonseca MA, Feigal RJ, ten Benseal RW. Dental aspects of 1248 cases of child maltreatment on file at a major county hospital. *Pediatr Dent*. 1992;14(3):152–157
14. American Academy of Pediatric Dentistry. Policy on emergency oral care for infants, children, and adolescents. *Pediatr Dent*. 2012/2013;234(6):245
15. Diangelis AJ, Andreasen JO, Ebeleseder KA, et al; International Association of Dental Traumatology. International Association of Dental Traumatology guidelines for the management of traumatic dental injuries: 1. Fractures and luxations of permanent teeth. *Dent Traumatol*. 2012;28(1):2–12
16. American Academy of Pediatric Dentistry. Guideline on Management of Acute Dental Trauma. *Pediatr Dent*. 2012/2013;234(6):230–238
17. American Academy of Pediatric Dentistry. Policy on prevention of sports-related orofacial injuries. *Pediatr Dent*. 2012/2013;34(6):67–70
18. Andersson L, Andreasen JO, Day P, et al; International Association of Dental Traumatology. International Association of Dental Traumatology guidelines for the management of traumatic dental injuries: 2. Avulsion of permanent teeth. *Dent Traumatol*. 2012;28(2):88–96

Management of Dental Trauma in a Primary Care Setting
Martha Ann Keels and THE SECTION ON ORAL HEALTH
Pediatrics 2014;133;e466; originally published online January 27, 2014;
DOI: 10.1542/peds.2013-3792

Updated Information & Services	including high resolution figures, can be found at: http://pediatrics.aappublications.org/content/133/2/e466.full.html
References	This article cites 16 articles, 2 of which can be accessed free at: http://pediatrics.aappublications.org/content/133/2/e466.full.html#ref-list-1
Citations	This article has been cited by 2 HighWire-hosted articles: http://pediatrics.aappublications.org/content/133/2/e466.full.html#related-urls
Subspecialty Collections	This article, along with others on similar topics, appears in the following collection(s): Dentistry/Oral Health http://pediatrics.aappublications.org/cgi/collection/dentistry:oral_health_sub Section on Pediatric Dentistry and Oral Health http://pediatrics.aappublications.org/cgi/collection/section_on_pediatric_dentistry_and_oral_health Preventative Medicine http://pediatrics.aappublications.org/cgi/collection/preventative_medicine_sub
Permissions & Licensing	Information about reproducing this article in parts (figures, tables) or in its entirety can be found online at: http://pediatrics.aappublications.org/site/misc/Permissions.xhtml
Reprints	Information about ordering reprints can be found online: http://pediatrics.aappublications.org/site/misc/reprints.xhtml

PEDIATRICS is the official journal of the American Academy of Pediatrics. A monthly publication, it has been published continuously since 1948. PEDIATRICS is owned, published, and trademarked by the American Academy of Pediatrics, 141 Northwest Point Boulevard, Elk Grove Village, Illinois, 60007. Copyright © 2014 by the American Academy of Pediatrics. All rights reserved. Print ISSN: 0031-4005. Online ISSN: 1098-4275.

American Academy of Pediatrics

DEDICATED TO THE HEALTH OF ALL CHILDREN™

