



Diagnosis, classification, and management of erythema multiforme and Stevens-Johnson syndrome

C Léauté-Labrèze, T Lamireau, D Chawki, J Maleville and A Taïeb

Arch. Dis. Child. 2000;83;347-352
doi:10.1136/adc.83.4.347

Updated information and services can be found at:
<http://adc.bmj.com/cgi/content/full/83/4/347>

These include:

References

This article cites 37 articles, 8 of which can be accessed free at:
<http://adc.bmj.com/cgi/content/full/83/4/347#BIBL>

10 online articles that cite this article can be accessed at:
<http://adc.bmj.com/cgi/content/full/83/4/347#otherarticles>

Rapid responses

You can respond to this article at:
<http://adc.bmj.com/cgi/eletter-submit/83/4/347>

Email alerting service

Receive free email alerts when new articles cite this article - sign up in the box at the top right corner of the article

Topic collections

Articles on similar topics can be found in the following collections

[Epidemiologic studies](#) (10977 articles)
[Immunology \(including allergy\)](#) (14120 articles)
[Drugs: infectious diseases](#) (2000 articles)
[Dentistry and oral medicine](#) (1269 articles)
[Dermatology](#) (2334 articles)

Notes

To order reprints of this article go to:
<http://journals.bmj.com/cgi/reprintform>

To subscribe to *Archives of Disease in Childhood* go to:
<http://journals.bmj.com/subscriptions/>

Diagnosis, classification, and management of erythema multiforme and Stevens–Johnson syndrome

C Léauté-Labrèze, T Lamireau, D Chawki, J Maleville, A Taïeb

Abstract

Background—In adults, erythema multiforme (EM) is thought to be mainly related to herpes infection and Stevens–Johnson syndrome (SJS) to drug reactions.

Aims—To investigate this hypothesis in children, and to review our experience in the management of these patients.

Methods—A **retrospective** analysis of 77 paediatric cases of EM or SJS admitted to the Children's Hospital in Bordeaux between 1974 and 1998.

Results—Thirty five cases, inadequately documented or misdiagnosed mostly as urticarias or non-EM drug reactions were excluded. Among the remaining 42 patients (14 girls and 28 boys), 22 had EM (11 EM minor and 11 EM major), 17 had SJS, and three had isolated mucous membrane involvement and were classified separately. Childhood EM was mostly related to herpes infection and SJS to infectious agents, especially *Mycoplasma pneumoniae*. Only two cases were firmly attributed to drugs (antibiotics). No patient died. EM and SJS sequelae were minor and steroids were of no overall benefit.

Conclusion—In paediatric practice EM is frequently misdiagnosed. The proposal that SJS is drug related in adults does not apply to children, and in our recruitment EM and SJS are mostly triggered by infectious agents. The course of both diseases, even though dramatic at onset, leads to low morbidity and mortality when appropriate symptomatic treatment is given.

(Arch Dis Child 2000;83:347–352)

Keywords: erythema multiforme; Stevens–Johnson syndrome

Erythema multiforme (EM) is an acute, self-limiting disease of the skin and mucous membranes described by Hebra in 1866¹; it is characterised by **symmetrically distributed skin lesions, located primarily on the extremities**, and by a **tendency for recurrences**. EM is said to be rare in childhood, and very few paediatric series concern EM.^{2–13} Most series include adults and children, and when they concern only children, Stevens–Johnson syndrome (SJS) and EM are not distinguished. In 1922 Stevens and Johnson described two children who had fever, conjunctivitis, stomatitis, and a generalised exanthema with skin lesions distinct from EM¹⁴; but in the past 30 years it has

become widely accepted that EM and SJS, as well as toxic epidermal necrolysis, are all part of a single “EM spectrum”. In both EM and SJS, pathological changes in the earliest skin lesion consist of the accumulation of mononuclear cells around the superficial dermal blood vessels; epidermal damage is more characteristic of EM with keratinocyte necrosis leading to multilocular intraepidermal blisters.⁵ In fact, there is little clinical resemblance between typical EM and SJS, and recently some authors have proposed a reconsideration of the “spectrum” concept and a return to the original description.^{15–17} According to these authors, the term EM should be restricted to acral distributed typical targets or raised oedematous papules. Depending on the presence or absence of mucous membrane erosions the cases may be classified as EM major or EM minor.¹⁶ The term SJS should be used for a syndrome characterised by mucous membrane erosions and widespread blisters, often predominant on the chest, and presenting with erythematous or purpuric macules.¹⁷

We have carried out a retrospective analysis of all patients under 15 years of age, hospitalised for EM or SJS over a 20 year period at the Children's Hospital in Bordeaux. Our aims were: (1) to classify childhood EM and SJS according to the clinical criteria of Bastuji-Garin and colleagues¹⁵; (2) to study in children the hypothesis that typical EM is mainly related to herpes simplex virus and SJS to drug reactions, as previously shown in adults¹⁷; and (3) to review our experience in the diagnosis and management of children with EM.

Patients and methods

Three of us (CLL, DC, and JM) reviewed all the records and photographs of 77 children admitted for EM or SJS in all paediatric wards of our hospital between 1974 and 1996.

CLINICAL CLASSIFICATION

All cases were classified according to the following criteria¹⁶:

- *EM minor*: typical targets or raised oedematous papules acral distributed (fig 1)
- *EM major*: as above, with involvement of one or more mucous membranes
- *SJS*: widespread blisters predominant on the chest, presenting with erythematous or purpuric macules and one or more mucous membrane erosions (fig 2).

CRITERIA FOR AETIOLOGICAL ATTRIBUTION

Herpes—Because herpes aetiology is questionable in most cases of EM, we decided to use the

Unité de Dermatologie
Pédiatrique, Hôpital
Pellegrin-Enfants,
Place Amélie
Raba-Leon, 33 076
Bordeaux Cedex,
France
C Léauté-Labrèze
J Maleville
A Taïeb

Service de Pédiatrie,
Hôpital
Pellegrin-Enfants
T Lamireau
D Chawki

Correspondence to:
Prof. Taïeb
email:
alain.taieb@u-bordeaux2.fr

Accepted 24 May 2000

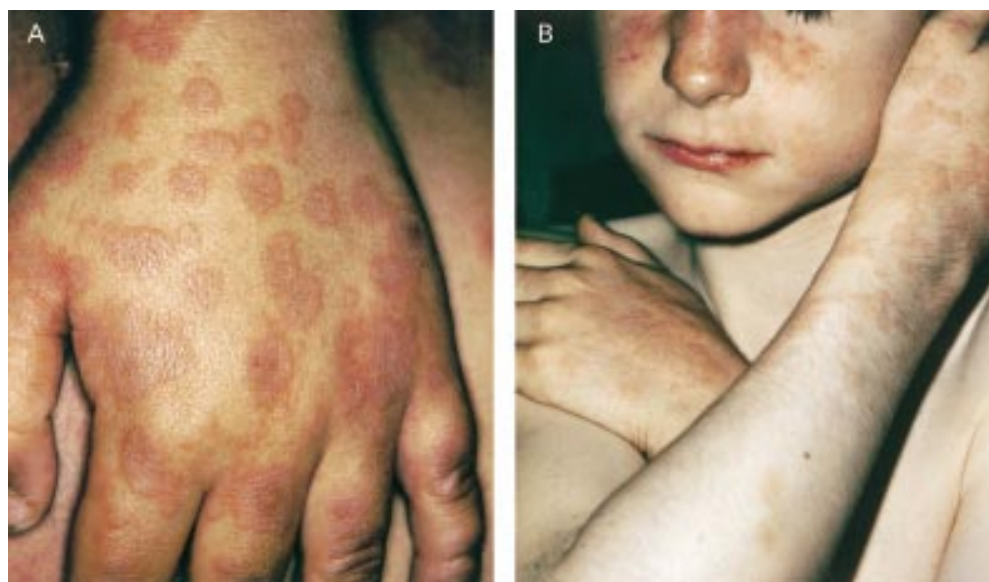

Figure 1 (A) Typical targets of EM associated with raised oedematous papules on hand. (B) Typical targets of EM acrally distributed in a child with labial herpes.

herpes score of Assier and colleagues.¹⁷ This score (0–4) was established by adding the following criteria (one point each): recurrent EM, history of recurrent herpes, recent clinical herpes (preceding EM within three weeks), and a demonstration of a recent herpes simplex virus infection (virus isolation, positive immunofluorescence, or seroconversion). EM was firmly attributed to herpes simplex virus infection for a score of 2 or more, without any other suspected aetiology. Herpes virus infection was only suspected for a score of 1.

SJS was only attributed to *Mycoplasma pneumoniae* (MP) when there was positive MP complement fixation titre and/or isolation of MP on throat cultures. MP was only suspected in cases of associated febrile pneumonia without bacteriological confirmation.

An infectious aetiology was suspected when a preceding illness was noticed without drug ingestion.

All drug ingestions during the preceding two weeks were recorded, and EM or SJS were attributed to drugs according to the official

French algorithm used for reporting adverse drug reactions.¹⁸ A score is calculated on the basis of chronological and semiological criteria of skin manifestations; a minimum score of 3 is required to suspect drug involvement. In case of drug intake during infection, the possible involvement of both causes was taken into account.

Results

Eleven cases were inadequately documented and excluded from the study.

DIFFERENTIAL DIAGNOSIS OF EM AND SJS

Twenty four of 66 cases were clearly not affected by EM or SJS. Among these patients nine had urticaria, seven had non-EM drug reactions (maculopapular rash in five cases and toxic pustuloderma in two cases), two children had papular urticaria, two others acute haemorrhagic oedema, and two cases had varicella. Kawasaki disease and staphylococcal scalded skin syndrome were also noted (one case each).

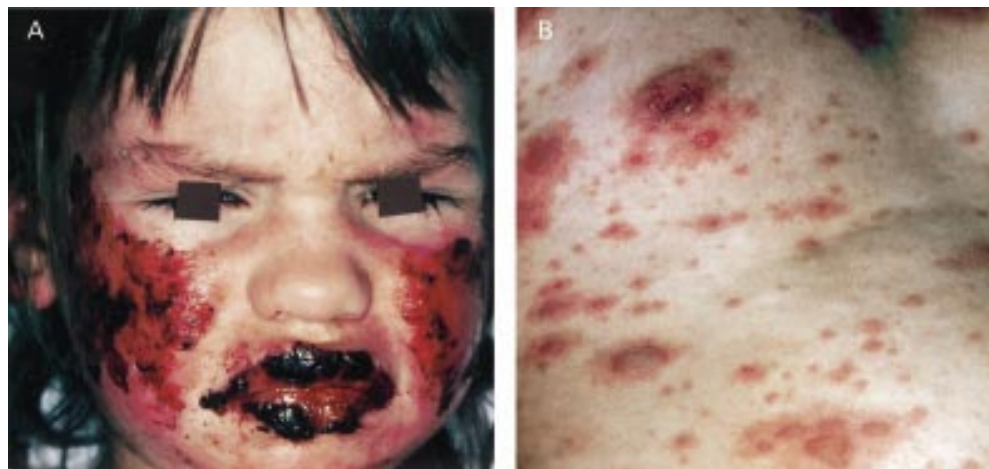

Figure 2 (A) SJS with skin and major mucous membrane involvement. (B) Widespread blisters of the chest in a child with SJS.

Table 1 Patients with erythema multiforme

No., sex	Age (y)	Preceding illness	Drug ingestion one week before	Suspected aetiology	Duration of disease	Steroids Yes/no	Recurrences Yes/no	Sequelae Yes/no
<i>Erythema multiforme minor</i>								
1, M	8 months	Immunisation*	None	Immunisation*	10 days	No	No	No
2, M	1	Immunisation‡	None	Immunisation*	10 days	No	No	No
3, F	4	Pharyngitis	Ampicillin (2)	Infection or antibiotics	10 days	No	No	No
4, M	6	None	None	Tuberculin	10 days	No	No	No
5, M	9	Labial herpes	None	Herpes (3)	10 days	No	Yes	No
6, F	9	Dyshidrosis	Oxacillin (2)	Herpes (1) or oxacillin	20 days	No	No	No
7, M	10	None	None	Herpes (1)?	15 days	No	Yes	No
8, M	11	Labial herpes	None	Herpes (2)	8 days	Yes	?	No
9, F	12	None	None	Herpes (2)?	15 days	No	Yes	No
10, M	15	Labial herpes	None	Herpes (2)	?	No	?	No
11, M	15	Labial herpes	None	Herpes (3)	8 days	No	Yes	No
<i>Erythema multiforme major</i>								
12, M	4	orf	Acyclovir (1)	orf	10 days	No	No	No
*13, M	6	Bronchoendoscopy	Ampicillin (3)	Ampicillin	10 days	No	No	No
*14, M	10	Tonsillitis	None	Streptococcus A?	15 days	No	No	No
15, F	10	None	None	Herpes (1)?	?	No	Yes	No
*16, F	12	?	None	Herpes (1)?	?	No	Yes	No
17, M	13	Immunisation*	None	Immunisation?†	?	Yes	Yes	No
18, M	13	Labial herpes	None	Herpes (3)	?	No	Yes	No
19, M	13	Labial herpes	None	Herpes (2)	?	No	?	No
*20, M	13	Labial herpes	None	Herpes (3)	?	No	Yes	No
21, F	14	Tonsillitis	Ampicillin (2)	Infection or drugs?	?	No	No	No
			Niflumic acid (2)					
*22, M	14	Upper respiratory tract infections	None	Sinusitis?	20 days	Yes + thalidomide	Yes	No

Herpes and drug scores are in brackets.

*Vaccine.

†Immunisation against diphtheria–tetanus–poliomyelitis.

‡Immunisation against measles–mumps–rubella.

CLINICAL CLASSIFICATION

Forty two patients could be evaluated: 22 children had EM (11 EM minor and 11 EM major), and 17 had SJS (tables 1, 2, and 3).

Three children had mucous membrane symptoms, without any cutaneous lesions. The eye, oral cavity, and genitalia were all involved. We were unable to classify these patients as EM major or SJS according to the criteria.

There was a male predominance (28 boys and 14 girls), especially in the group of EM patients (16 boys and six girls, sex ratio 2.6).

Mean age was 8.7 years (range 8 months to 15 years). The mean age of EM patients was higher than that of SJS patients (9.7 years versus 7.8 years).

AETIOLOGY OF THE DISEASE

Infections

In 27 patients, aetiology of the disease was attributed to infectious agents: 14 of 22 cases of EM, 11 of 17 cases of SJS; and two of three patients with mucous membrane involvement.

Herpes was associated with EM but not SJS. In eight of 22 patients, EM was attributed to

Table 2 Patients with Stevens–Johnson syndrome and mucous membrane involvement only

No., sex	Age (y)	Preceding illness	Drug ingestion one week before	Suspected aetiology	Duration of disease	Steroids Yes/no	Recurrences Yes/no	Sequelae
<i>Stevens–Johnson syndrome</i>								
23, F	2	Measles	No	Measles or immunisation*	12 days	No	No	No
24, F	4	Hyperthermia	No	Infection	20 days	No	No	Cutaneous dyschromia
25, F	5	Upper respiratory tract infection	No	M <i>pneumoniae</i> ?	15 days	No	No	No
26, M	6	Pneumopathy	No	M <i>pneumoniae</i>	15 days	Yes	No	No
27, M	6	Pneumopathy	Ampicillin (2)	M <i>pneumoniae</i>	12 days	No	No	No
			Ibuprofen (2)			Thalidomide		
28, M	7	Hyperthermia	No	Infection	20 days	Yes	No	Labial synechiae
29, F	7	Pneumopathy	No	M <i>pneumoniae</i>	20 days	Yes	No	Ocular synechiae
30, M	8	Pneumopathy	No	M <i>pneumoniae</i> ?	20 days	Yes	No	Dyschromia
31, M	8	Pneumopathy	No	M <i>pneumoniae</i> ?	20 days	No	No	No
32, M	8	Pneumopathy	Ampicillin (2)	Infection or ampicillin	10 days	Yes	No	No
33, M	9	Hyperthermia	No	M <i>pneumoniae</i>	30 days	No	No	No
34, F	9	Meningococemia	Ampicillin (2)	Meningococcus or drugs	10 days	No	No	No
			Clonazepam (2)					
35, M	9	Upper respiratory tract infection	Ampicillin (2)	M <i>pneumoniae</i> or drug	20 days	No	No	Ocular synechiae
36, F	12	Pneumopathy	No	M <i>pneumoniae</i>	20 days	No	No	Labial synechiae
		Immunisation‡		or immunisation‡				
37, M	12	Upper respiratory tract infection	No	Infection	10 to 30 days	Yes + thalidomide	Yes	No
38, M	13	Pneumopathy	No	M <i>pneumoniae</i>	20 days	No	No	No
39, F	13	None	Sulfamethoxyipyridamide (3)	Drug	20 days	No	No	No
<i>Mucous membrane involvement only</i>								
40, F	4	Hyperthermia	No	Herpes? (1)	10 days	No	No	No
41, M	10	Immunisation*	No	Immunisation?†	20 days	No	No	No
42, M	13	Labial herpes	Ampicillin (2)	Herpes (2) or drug	10 days	Yes	Yes	No

Herpes and drug scores are in brackets.

*Vaccine.

†Diphtheria–tetanus–poliomyelitis.

‡Hepatitis B.

Table 3 Summary of causes in EM and SJS patients

	EM	SJS	Total
Herpes	8 (+4?)	0	12
<i>M pneumoniae</i>	0	5 (+5?)	10
Other infection and/or immunisation	7	5 (including 1 MP)	12
Infection and/or drug	3 (including 1 herpes)	3 (including 1 MP)	6
Drug	1	1	2
Total	22	17	

herpes infection and in four other cases, herpes was strongly suspected. Recurrent labial herpes infection was responsible for eight of 10 cases of recurrent EM.

Mycoplasma pneumoniae was responsible for five of 17 cases of SJS, and strongly suspected in five others because of pulmonary symptoms during the disease.

Other infectious agents and immunisation—One case of EM (case 12) was associated with orf (ecthyma contagiosum). Streptococcus A was suspected in one case of EM (case 14), and meningococcus C in one case of SJS (case 34), although the girl had received drugs before the onset of cutaneous signs. Six cases (three EM, two SJS, and one mucous membrane involvement) could be attributed to immunisation 10 days before the onset of the disease (vaccine: diphtheria–tetanus–poliomyelitis in two; measles–mumps–rubella in one; and hepatitis B in one). However, in two cases, an infectious disease was also associated.

Drugs

Fewer than 5% of patients had any disease attributed to drug intake only (two of 42 cases). These two cases were attributed to antibiotics (sulphamethoxypyridamine in SJS, case 39; and amoxycillin in EM, case 13). In eight cases, children were given antibiotics, mostly β lactams, because of infectious symptoms at the onset of the disease. However, drug involvement could not be assessed according to current criteria.¹⁸

OUTCOME AND FOLLOW UP

No patient died. The mean duration of the disease was 12 days for EM and 18 days for SJS patients. Forty five per cent of EM patients had recurrent disease (10 cases of 22).

Ten patients received corticosteroids (prednisone or prednisolone 1 mg/kg/day for one week with progressive decrease). The mean disease duration was 16 days in patients treated with steroids (10 patients) versus 15 days in the non-steroid treated group.

Three patients received thalidomide for either acute illness (one case of SJS) or severe recurrent disease (one case of EM major and one case of SJS). While the patient with recurrent EM major was well controlled by thalidomide (case 22), the one with recurrent SJS, a 12 year old boy (case 37) had a severe recurrent disease of unknown aetiology (eight relapses in four years) with primary severe mucous membrane involvement and digestive bleeding as a result of oesophageal involvement confirmed by endoscopy. Relapses were initially controlled by thalidomide taken in the first hours of the disease, but then a severe relapse with skin

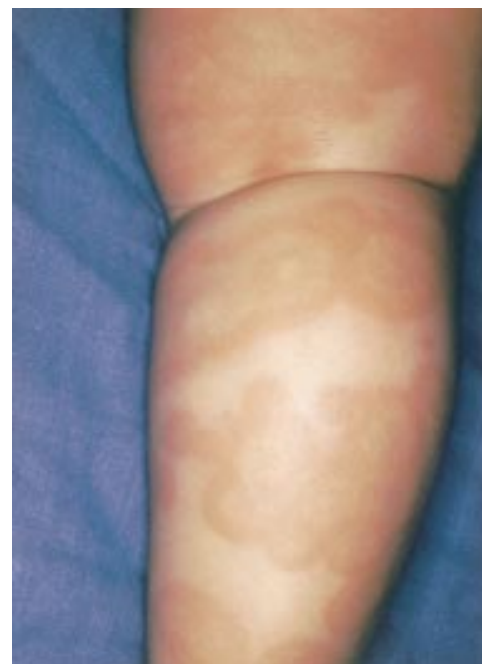

Figure 3 Example of most frequent EM misdiagnosis, acute urticaria with haemorrhagic cockade pattern.

involvement occurred as a result of MP infection and did not respond to the treatment.

Sequelae were minor in most cases including skin pigmentary changes, lip scars, mild ocular synechiae, and psychological disturbances in some cases of recurrent disease.

Discussion

In our series almost one third of children (24 of 77 cases) admitted to hospital for a suspected diagnosis of EM or SJS were misdiagnosed. The term EM is still confusing to non-dermatologists and is usually applied to many acute eruptive disorders; usually the diagnosis can be easily corrected by a dermatologist or a consultant in paediatric dermatology. The most common misdiagnosis is acute urticaria, especially in cases of ecchymotic cockade pattern in infants^{19 20} (fig 3). Other differential diagnoses include Kawasaki syndrome (fig 4) when there is cockade pattern rash or major mucous membrane involvement, acute haemorrhagic oedema,²¹ and maculopapular rash caused by drug intake.

In our experience, both EM and SJS can be considered as infection driven disorders. Even though the aetiology remains unclear in some patients, in most an infectious aetiology may be suspected on the grounds of various clinical, laboratory, and radiological arguments. The causes seem to be more viral than bacterial, except in MP infections.^{22 23} In this series, MP infection was responsible for almost two thirds of SJS cases, but was never associated with typical EM eruption. Thirty per cent of SJS patients had proven MP infection and in 30% of the other cases MP infection could be suspected because of pulmonary symptoms. In childhood SJS, the probability of MP infection is high and the use of antibiotics such as erythromycin, which are usually effective against MP, as first line treatment, can be advised.

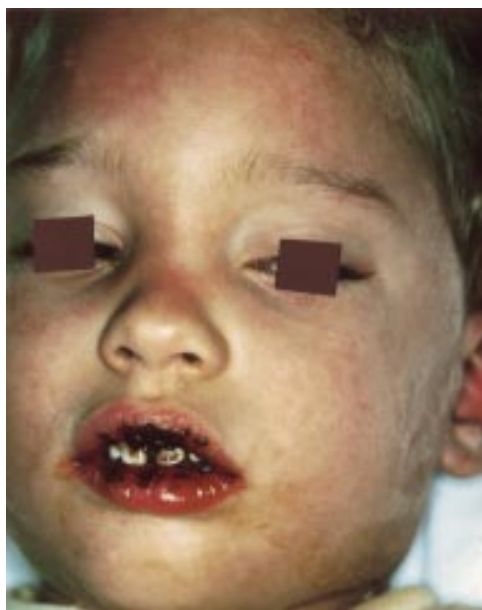

Figure 4 Kawasaki disease mimicking mucous membrane involvement of SJS.

Concerning viruses, our series confirms that typical childhood EM is related to herpes infection,^{5 6 10 13 17} as is recurrent EM.^{24 25} A labial herpes outbreak was noticed in 32% of cases and a recurrent labial herpes in 54% of EM cases (80% in recurrent EM). Unfortunately, it was retrospectively impossible to perform a polymerase chain reaction and isolate herpes DNA in skin lesions.²⁶ No case of SJS could be attributed to herpes. Other viruses were incriminated in our series: orf (ecthyma contagiosum) in one case of EM (case reported in Ferrando and colleagues²⁷); paravaccinia (cowpox) in one case of EM and one case of SJS; and paramyxovirus (measles) in one case of SJS.

EM and SJS were also associated with immunisation with living replicative viruses (measles), or viral antigens like those used in hepatitis B immunisation.²⁸ In two cases the disease followed diphtheria and tetanus toxoid vaccination,²⁹ and in one case EM was triggered by a tuberculin test, supporting the

hypothesis that EM and SJS are a host specific response to a wide variety of infectious antigenic stimuli.

A similar phenomenon can be noted for adverse cutaneous drug reactions: cutaneous eruption may vary from benign maculopapular rash to Lyell syndrome and depend mainly on the host response to a single drug.³⁰ Although Lyell syndrome in children is mainly a result of drug intake,^{8 31–33} in our experience EM and SJS are rarely related to medications. In both EM and SJS, many children were given drugs at the onset of the disease, especially antibiotics. However, the involvement of the drug could not be assessed. Only two cases were definitely attributed to drugs, the children having polymorphic cutaneous lesions, including maculopapular rash, target like macules, and major polymorphic cutaneous lesions with blisters. In one case typical targets of EM were present in association with mild mucous membrane involvement, so we diagnosed EM major and not SJS according to the criteria (case 13, figs 1A and 5). The association in the same patient of various cutaneous lesions, such as pseudocockade pattern and blisters should point to drug eruption.

The use of corticosteroids is a still debated issue in EM of SJS.^{2 34–36} Some of our patients received corticosteroids, without any benefit in term of disease duration compared to children treated only with supportive care. Even though some authors recommend infusions of methylprednisolone in SJS,³⁶ this treatment should be considered with circumspection, especially if an infectious aetiology is suspected.

The value of acyclovir in recurrent cases could not be assessed in this series.³⁷ Thalidomide was used in severe or recurrent disease but it was retrospectively difficult to evaluate efficacy; and recently a detrimental effect has been reported in patients with toxic epidermal necrolysis.³⁸

In EM and SJS careful symptomatic treatment is essential.^{8 23 31–33} Nursing should

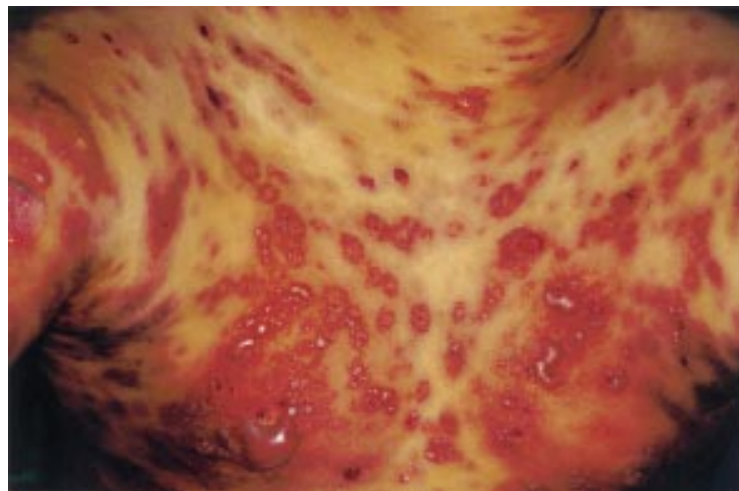


Figure 5 Blisters on the chest in a child with EM major (same patient as fig 1A).

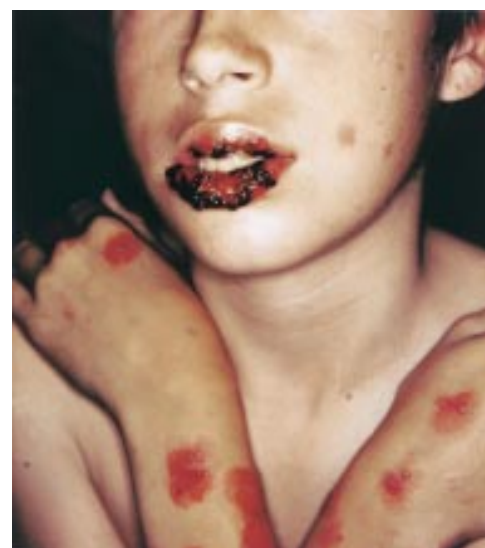

Figure 6 Atypical EM showing blisters on purpuric macules acraly distributed in a child with labial herpes.

include meticulous skin and mucous membrane care, **daily ophthalmological examination**, and long term follow up when necessary. Antibiotic treatment is not thought to be necessary, except in case of MP infection. In children, severe cases of SJS are frequently complicated with major mucous membrane and oesophageal involvement, and intravenous fluids associated with nutritional support through a gastric tube may be helpful. With such symptomatic treatment, morbidity and sequelae are minor.

A standardised EM and SJS classification may be helpful for prospective investigations concerning their aetiology and physiopathology. Although consensus was easily obtained between the three experts in most cases of EM minor, it was more difficult to reach in some cases of EM major and SJS. Indeed, our children often presented both typical and atypical targets in association with blisters (figs 1A and 5). On the other hand, atypical targets and purpuric macules were also seen in a typical acrally distributed EM pattern (fig 6). Furthermore, **three children had only mucous membrane involvement and were unclassifiable. We arbitrarily decided to classify patients as EM major and not SJS if typical cockades were present**; however, this point is questionable, and suggests that an aetiological classification would be more satisfactory than a clinical classification based solely on skin eruption.

In conclusion, careful enquiry into drug intake is recommended, especially in cases of SJS or atypical EM; however, a drug induced eruption is not so frequent in our paediatric experience. Many viruses or bacteria can be trigger agents of EM and SJS, but the majority of cases are related to herpes and MP. MP infection is responsible for childhood SJS, a very severe condition justifying admission to a specialised unit. Herpes virus is responsible for typical minor or major EM and in most cases the disease is benign, even though of dramatic presentation. The main problem is recurrent EM which may require chronic therapy with acyclovir; thalidomide should be reserved for the most severe cases.

- 1 Hebra F von. *Atlas der Hautkrankheiten*. Vienna: Kaiserliche Akademie der Wissenschaften Wien, 1866.
- 2 Rasmussen JE. Erythema multiforme in children. Response to treatment with systemic corticosteroids. *Br J Dermatol* 1976;**95**:181–6.
- 3 Ginsburg M. Stevens-Johnson syndrome in children. *Pediatr Infect Dis* 1982;**1**:155–8.
- 4 Maleville J, Massicot P, Ponge A, Guillard JM, Sarraz P, Guillet G. Aspects cliniques et étiologiques de l'érythème polymorphe. *Sem Hôp Paris* 1983;**59**:671–5.
- 5 Huff JC, Weston WL, Tonnesen MG. Erythema multiforme: a critical review of characteristics, diagnostic criteria, and causes. *J Am Acad Dermatol* 1983;**8**:763–75.
- 6 Howland WW, Golitz LE, Weston WL, Huff JC. Erythema multiforme: clinical, histopathologic, and immunologic study. *J Am Acad Dermatol* 1984;**10**:438–46.
- 7 Dikland WJ, Oranje AP, Stolz E, van Joost T. Erythema multiforme in childhood and early infancy. *Pediatr Dermatol* 1986;**3**:135–9.
- 8 Prendiville S, Hebert A, Greenwald J, Esterly B. Management of Stevens-Johnson syndrome and toxic epidermal necrolysis in children. *J Pediatr* 1989;**115**:881–7.

- 9 Chan HL, Stern RS, Arndt KA, Langlois J, Jick SS, Jick H, Walker AM. The incidence of erythema multiforme, Stevens-Johnson syndrome, and toxic epidermal necrolysis. *Arch Dermatol* 1990;**126**:43–7.
- 10 Hurwitz S. Erythema multiforme: a review of its characteristics, diagnostic criteria, and management. *Pediatr Rev* 1990;**11**:217–22.
- 11 Salomon D, Saurat JH. Erythema multiforme major in a 2-month-old child with human immunodeficiency virus (HIV) infection. *Br J Dermatol* 1990;**123**:797–800.
- 12 Wolf P, Soyer HP, Fink-Puches R, Huff JC, Kerl H. Recurrent post-herpetic erythema multiforme mimicking polymorphic light and juvenile spring eruption: report of two cases in young boys. *Br J Dermatol* 1994;**131**:364–7.
- 13 Weston WL, Morelli JG, Rogers M. Target lesions on the lips: childhood herpes simplex associated with erythema multiforme mimics Stevens-Johnson syndrome. *J Am Acad Dermatol* 1997;**37**:848–50.
- 14 Stevens AM, Johnson FC. A new eruptive fever associated with stomatitis and ophthalmia. *Am J Dis Child* 1922;**24**:526–33.
- 15 Bastuji-Garin S, Rzany B, Stern RS, Shear NH, Naldi L, Roujeau JC. Clinical classification of cases of toxic epidermal necrolysis, Stevens-Johnson syndrome, and erythema multiforme. *Arch Dermatol* 1993;**129**:92–6.
- 16 Roujeau JC. What is going on in erythema multiforme? *Dermatology* 1994;**188**:249–50.
- 17 Assier H, Bastuji-Garin S, Revuz J, Roujeau JC. Erythema multiforme with mucous membrane involvement and Stevens-Johnson syndrome are clinically different disorders with distinct causes. *Arch Dermatol* 1995;**131**:539–43.
- 18 Begaud B, Evreux JC, Jouglaud J, Lagier G. Imputabilité des effets inattendus ou toxiques des médicaments. *Thérapie* 1989;**44**:223–7.
- 19 Legrain V, Taïeb A, Sage T, Maleville J. Urticaria in infants: a study of forty patients. *Pediatr Dermatol* 1990;**7**:101–7.
- 20 Mortureux P, Léauté-Labrèze C, Legrain-Lifermann V, Lamireau T, Sarlangue J, Taïeb A. Acute urticaria in infancy and early childhood. A prospective study. *Arch Dermatol* 1998;**134**:319–23.
- 21 Legrain V, Lejean S, Taïeb A, Guillard JM, Battin J, Maleville J. Infantile acute hemorrhagic edema of the skin: study of ten cases. *J Am Acad Dermatol* 1991;**24**:17–22.
- 22 Sontheimer RD, Garibaldi RA, Krueger GG. Stevens-Johnson syndrome associated with Mycoplasma pneumoniae infections. *Arch Dermatol* 1978;**114**:241–4.
- 23 Tay YK, Huff C, Weston WL. Mycoplasma pneumoniae infection is associated with Stevens-Johnson syndrome, not erythema multiforme (von Hebra). *J Am Acad Dermatol* 1996;**35**:757–60.
- 24 Schofield JK, Tatnall FM, Leign IM. Recurrent erythema multiforme: clinical features and treatment in a large series of patients. *Br J Dermatol* 1993;**128**:542–5.
- 25 Huff JC, Weston WL. Recurrent erythema multiforme. *Medicine* 1989;**68**:133–40.
- 26 Brice SL, Krzemien D, Weston WL, Huff JC. Detection of herpes simplex virus DNA in cutaneous lesions of erythema multiforme. *J Invest Dermatol* 1989;**93**:183–7.
- 27 Ferrando MF, Léauté-Labrèze C, Fleury H, Taïeb A. Orf and erythema multiforme in a child. *Pediatr Dermatol* 1997;**14**:154–5.
- 28 Di Iernia V, lo Scocco G, Bisighini G. Erythema multiforme following hepatitis B vaccine. *Pediatr Dermatol* 1994;**11**:363–4.
- 29 Griffith RD, Miller OF. Erythema multiforme following diphtheria and tetanus toxoid vaccination. *J Am Acad Dermatol* 1998;**19**:758–9.
- 30 Bergeond H, Löffler A, Maleville J. Réactions cutanées survenues au cours de la prophylaxie de masse de la méningite cérébrospinale par un sulfamide long-retard. *Ann Dermatol* 1968;**95**:481–90.
- 31 Teillac D, Marsol P, Richard P, Hubert P, Roujeau JC, Cloup M, de Prost Y. Nécrolyse épidermique toxique de l'enfant (syndrome de Lyell). A propos de 18 cas. *Arch Fr Pediatr* 1987;**44**:583–7.
- 32 Adzick NS, Kim SH, Bondoc CC, Quinby WC, Remensnyder JP. Management of toxic epidermal necrolysis in a pediatric burn center. *Am J Dis Child* 1985;**139**:499–502.
- 33 Barone CM, Bianchi MA, Lee B, Mitra A. Treatment of toxic epidermal necrolysis and Stevens-Johnson syndrome in children. *J Oral Maxillofac Surg* 1993;**51**:264–8.
- 34 Esterly NB. Corticosteroids for erythema multiforme? *Pediatr Dermatol* 1989;**6**:229–50.
- 35 Renfro L, Grant-Kels JM, Feder HM Jr, Daman LA. Controversy: are systemic steroids indicated in the treatment of erythema multiforme. *Pediatr Dermatol* 1989;**6**:43–50.
- 36 Kakourou T, Klontza D, Soteropoulou F, Kattamis C. Corticosteroid treatment of erythema multiforme major (Stevens-Johnson syndrome) in children. *Eur J Pediatr* 1997;**156**:90–3.
- 37 Bahmer FA, Zaun H, Luszpinski P. Thalidomide treatment of recurrent erythema multiforme. *Acta Derm Venereol* 1982;**62**:449–50.
- 38 Wolkenstein P, Latarjet J, Roujeau JC, et al. Randomised comparison of thalidomide versus placebo in toxic epidermal necrolysis. *Lancet* 1998;**352**:1586–9.